



**PURE SCIENCES INTERNATIONAL  
JOURNAL OF KERBALA**



Year:2024

Volume : 1

Issue : 3

ISSN: 6188-2789 Print

3005 -2394 Online

Follow this and additional works at: <https://journals.uokerbala.edu.iq/index.php/psijk/AboutTheJournal>

This Original Study is brought to you for free and open access by Pure Sciences International Journal of kerbala  
It has been accepted for inclusion in Pure Sciences International Journal of kerbala by an authorized editor of Pure Sciences .  
/International Journal of kerbala. For more information, please contact [journals.uokerbala.edu.iq](https://journals.uokerbala.edu.iq)

Shaymaa Malik Yasir, Hanaa Mumtaz Hussein, Dalal Abdel-Hussein Kadhim AL-Essawi, Histological Influences and Liver Weight Measurements in Female Rats and Their Embryos After Spasmine Drug Administration, Pure Sciences International Journal of Kerbala, Vol. 1 No. 3, (2024) 79-87



## Histological Influences and Liver Weight Measurements in Female Rats and Their Embryos After Spasmin Drug Administration

Shaymaa Malik Yasir<sup>1\*</sup>, Hanaa Mumtaz Hussein<sup>2</sup>, Dalal Abdel-Hussein Kadhim AL-Essawi<sup>3</sup>

<sup>1</sup>Biology Department, College of Education for Pure Sciences, Kerbala University, Kerbala, Iraq

<sup>2,3</sup>Biology Department, Education for Girls Faculty, Kufa University, Iraq

### PAPER INFO

Received: 5 September 2024  
Accepted: 26 September 2024  
Published: 30 September 2024

#### Keywords:

Spasmin, Weights, Livers, Embryo, Pregnant, Rats, Histological Influences.

### ABSTRACT

A study was conducted to determine the role of spasmin in some weight and histological parameters of the livers of pregnant female rats and their fetuses on the nineteenth day of pregnancy. The study was conducted at the College of Education for women at the University of Kufa for the period from January 1- 2022, until June 15- 2022. After obtaining 8 pregnant rats, 4 of them were dosed with a dose of the physiological solution. This group represented the control (G1), while 4 pregnant female rats were dosed with spasmin drug at a dose of (0.48 mg/kg/body weight) (G2) for 19 days. The pregnant rats in the control group were (12) weeks old and weighed (231) grams, while the pregnant animals in the group treated with spasmin were (11) weeks old and weighed (230) grams.

The results of the study recorded a significant decrease ( $P < 0.05$ ) in the liver weights of both pregnant animals and their fetuses in groups of rats treated with spasmin. The results also showed that treating rats with spasmin until the nineteenth day of pregnancy led to histopathological and abnormal changes in liver tissue such as damage to the central vein wall, hepatocyte necrosis, sinusoidal expansion, hepatic tissue necrosis and inflammatory cell infiltration in pregnant rats and their fetuses compared to pregnant rats and their fetuses in control groups during pregnancy on the nineteenth day.

The study concludes that the treatment with spasmin drug reduced the weight of pregnant animals and embryos' liver of embryos and also caused various histopathological changes in the structure of the livers of the pregnant rats and their embryos during the 19th day of gestation.

### 1. INTRODUCTION

Medical drugs are prescribed for the treatment of many diseases, as each drug has a therapeutic effect for different diseases but these drugs may cause many side effects that may be mild in some or severe in other types of them which affect many body systems. Since the wrong and unauthorized use of drugs induces dangerous and threatening effects on humans [1,2], some studies have pointed to that different drugs may pass through the placenta from the mother to the embryo during the different stages of gestation causing harmful effects in the body systems of pregnant women and their embryos alike. This happens because these drugs when they enter the body the pharmacological action is not limited to the affected organs but they cause harmful effects on the healthy organs of the body as well when they are present in them. This is due to the fact that they stimulate disorders in their metabolic functions [3,4], as these drugs have the ability to stimulate congenital disorders in embryos during gestation and newborns after birth and even adults alike. This may cause death

and for this reason many drugs are prepared during the different stages of gestation to ensure the safety of these medical drugs as the stage of gestation is critical for mothers as well as embryos [5]. The spasmin medication is classified as a p-methoxybenzoic acid derivative and it is commonly used to treat gastrointestinal disorders. Specifically, it functions as an antispasmodic to alleviate symptoms associated with chronic irritable colon, colitis of spastic and mucous and irritable bowel syndrome, and spastic constipation. Its mechanism of action involves direct sedation and muscle relaxation of the smooth muscles within the digestive system, thereby reducing painful cramps. Additionally, Spasmin is effective in treating accompanying symptoms of irritable bowel syndrome, including intestinal colic, flatulence, diarrhoea, constipation, and the passage of small, hard stools. The exact mechanism of action of this drug is still unknown but it is considered one of the antispasmodic effect through its direct activity on a smooth muscles of the digestive system. This causes these muscles to relax without impacting the normal bowel movement and several mechanisms are postulated to construe the action of spasmin on the digestive system. The most

\*Corresponding Author Institutional Email:  
[shaymaa.malik@uokerbala.edu.iq](mailto:shaymaa.malik@uokerbala.edu.iq) (Shaymaa Malik Yasir)

important one is that the inhibition of receptors for acetylcholine, alters in the process for water absorption, reduced permeability of ion channels, local anesthetic effects in addition to the reuptake inhibitor of norepinephrine [8,9]. Spasmin drugs come in multiple forms such as oral capsules and pills in addition to oral liquid [10]. The efficiency of this drug begins about an hour after taking it and the patient feels the disappearance of pathological symptoms after (1-3) hours of implementing the drug. However, this period may increase depending on the health status of patients [11]. Spasmin drug is like any other drug whose use is supported by some side effects like as loss of appetite, dry mouth, skin irritation headache, insomnia, depression, heartburn, indigestion, difficulty sleeping, diarrhoea, feeling unwell and tired, slow heartbeat, immune system disorders such as allergic responses causing hypersensitivity which appear in the form of skin rashes, urticaria and facial edema. Taking this drug with other drugs or certain meals may cause interactions that may reduce the effectiveness of the drugs used as the effectiveness of one drug might reduce the effectiveness of the other drug or may affect the patient's health [12,13]. The purpose of the study is due to the lack of research and studies on the impact of spasmin on the tissue of the liver during pregnancy. That is, the present study investigates the potential impact of spasmin drugs on weights as well as histological structures of the livers of pregnant rats and their embryos for gestation of nineteenth day.

## 2. MATERIALS AND METHODS

### 2.1. Study Animals

White female of rat animals from species *Rattus rattus* with ages ( 12 weeks )and weights (231g) were used, along with white male of rats from same species in a typical ages ( 11 weeks )and a weights (229 g). These animals were obtained to the College of Sciences / University of Kufa, and both sexes were housed in plastic cages with identical ventilation, temperature, and lighting conditions.

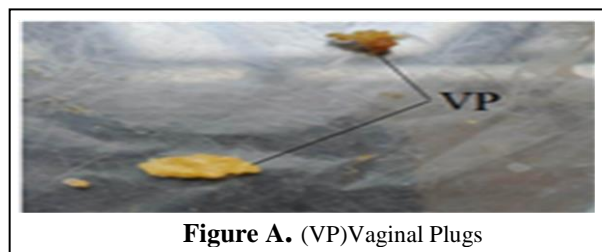
### 2.2. Drug Dose

Spasmin was administered in pill form at a dose of 100 mg. The concentration for the study was adjusted based on the weight of the animals and then administered to pregnant rats.

### 2.3. Pregnant Rats

To obtain pregnant female rats, a single adult female rat was placed with one fertile male rat in every pairing up a cage in the evening, and the animals were left overnight. The following morning, the female rats were tested for seeing the vaginal plug in the female's

vagina or in cage and as depicted in Figure A .It was determined that gestation had occurred based on the presence of the vaginal plug, which was thought about the zero-day of gestation. [14]



**Figure A.** (VP)Vaginal Plugs

### 2.4. Experiment Design

This study's main experiment was designed to examine the probable side impacts of spasmin on weights and tissue modifications of livers in embryos and pregnant rat animals treated of this drug during gestation for 19th day. After mating male and female rats and obtaining pregnant rats, 8 pregnant rats:4 of them as control group (G1) and 4 of pregnant female rats were given in spasmin drug at the dose of (0.48 mg/kg / b.w.) (G2) by peritoneal intramembranous injection at the rate of one injection per day for 19 days of gestation.

### 2.5. Pregnant Rats Dissection

Pregnant rats were annotated on the 20th day of gestation after being anesthetized with chloroform the pregnant rodents were pinned to a dissection dish before the abdominal cavity was cut opened with pointed scissors. the livers of the pregnant rats were extracted and washed with a physiological solution and dried with filter paper. Their weight was measured by a normal weight balance, the uterine horns containing the embryos were also removed after removing the connective tissue and the fatty substances attached to it.

### 2.6. Embryos Dissection

After pregnant female rats dissection during gestation for 20th days, the two uterus horns and its contents of the embryos, then two horns of the uterus were opening by scissors to extract the embryos which were washed with physiological solution and dried with filter paper, then the embryos were anesthetized by placing a quantity of chloroform in the cotton, after that they were dissected by opening the cavity abdominal and the livers were extracted from the body and their weights were measured with a sensitive balance, then embryo livers were preserved with formalin solution at a concentration of 10% for 48 hours in order to prepare them for histological sections.

### 2.7. Histological Section of Livers of Pregnant Rats and Embryos

During gestation for 19th days, tissue sections of livers of pregnant animals and their embryos were made using this method. [15]

### 2.8. Examination of Histological Liver Sections Embryos

The sections of liver tissues of all pregnant rats and their embryos during gestation for 19th days were prepared. Then, these tissue sections were examined and photographed using a MEIJT light microtope equipped with a samsung imaging camera installed on the microscope and on the powers (10X and 40X) respectively.

### 2.9. Statistically Data Analysis

The studied data were calculated by using the statistical system (SPSS) for version 21. Values were mean  $\pm$  standard error and ( $P < 0.05$ ) was a probability level used in this study to extract the least significant differences (LSD) for determining the significant differences among the groups. [16]

## 3. RESULTS AND DISCUSSION

Results of the study revealed a significant decrease at the probability level ( $P < 0.05$ ) in the liver weights of pregnant rats and embryos in the spasmine drug-treated pregnant rat group during the 19th day of gestation respectively when compared with the pregnant rat animals liver weights and embryos in group of control in a day 19 of gestation as shown in Table 1 and Table 2 respectively. Concerning the results of the histological study of the livers of the embryos whose mothers were handled with the spasmine drug, they suffered from different pathological effects on its histological structure. It was represented by the loss of the general structure of the hepatic tissue which may be a result of the lack of development and growth of a hepatic tissue. The developed tissue can be observed many pathological changes such as destruction of the central vein wall, necrosis and degeneration of hepatocyte, expanding of sinusoids, congestion and necrosis of hepatic tissue, bleed clotting and inflammatory cell infiltration as shown in the Figures (2,3,4,6,7,8,9,10,11,12,13 and 14) respectively when compared with the normal histological framework of the livers of embryos in the control group, Figures (1,5) and the examination results of histological sections of pregnant rats livers in control animals throughout 19<sup>th</sup> day of gestation which did not show any abnormal changes as shown in the Figures (15,19) respectively. The histological results of sections of pregnant female livers that were given with spasmin during the 19th day of gestation demonstrated different histopathological

changes represented by expansion and destruction of the central vein wall, necrosis and degeneration of hepatocyte, widening of sinusoids, bleeding into hepatic tissue and blockages, necrosis and damage of hepatic tissue and inflammatory cell infiltration as in Figures (16,17,18, 20,21,22,23,24,25 and 26) respectively.

In view of lack of sufficient researches of spasmine drug effect on weights and structure of the various organ tissues of the body especially the liver in pregnant rats during gestation or in embryos throughout the different stages of gestation, these results in this research can be attributed to the fact that spasmine drug caused the decrease in pregnant animal liver weights and the embryos due to its toxic effect which stimulated pathological effects on the histological structure of the liver during gestation as a result of its induction of programmed cell passing away (Apoptosis) and necrosis in addition to the occurrence of degenerative changes in it causing a destruction of the hepatic tissue and others organ tissues of the rats and the failure of the development and destruction of the liver tissue of embryos causing decrease in the weight of the livers in them. This is what the electricity study showed [17,18], or it may be because that spasmine drug is the cause of the destruction of various pregnant rats' tissues, especially the horns of the uterus and placenta leading to a decrease of oxygen and various nutrients necessary for growth to embryos during gestation which triggered the destruction of different body tissues like livers and its absence of their growth and low weights [19]. As for the histopathological effects induced by the drug under study in the liver tissues of pregnant rats and embryos during nineteen days of gestation, it may be due to the ability of spasmine drug on the generation of free radicals in cells and organs of the body in general and liver tissue cells particularly causing programmed death of cells and necrosis thus destroying and wrecking liver tissue [20] as the production of free radicals, which are potent oxidising factors, stimulates the oxidation process of lipids in cell membranes as well as other essential macromolecules inside cells such as nuclear acidic substances (DNA), proteins, and others, causing oxidative stress to every part of the body including cells of the liver tissue, which ultimately results in necrosis of the cells for the various tissues and thus destroys them. This may be attributed to the fact that free radicals are effective oxidising factors [21], the free oxygen radicals arising from various medical drugs including spasmine plays a consequential role in the breakdown in body organs, as they are strong oxidizing agents for lipids in cell membranes causing their destruction especially when their levels exceed normal levels stimulating oxidative stress which leads to the depletion for various self-antioxidants in the body that it works to inhibit a activity of free radicals and stop their

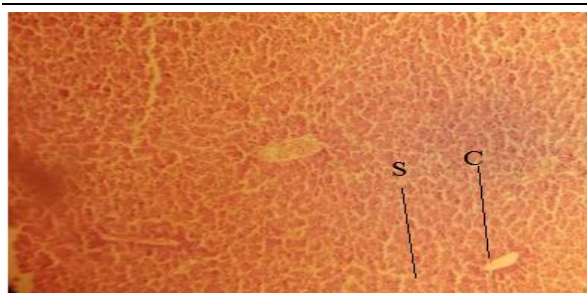
destructive action to the cells of various organs but when the levels for free radicals exceed the levels of antioxidants and the destructive action of cells as well as tissues of these free radicals will increase stimulating distinct histological impacts on the tissue structure of the liver and other body systems in pregnant rats and eggs in which the systems of the defense against antioxidants is weak and that they are not developed to counter the action of free radicals generated by the drug when it passes from the mother to a embryo through the placenta blood leading to oxidative destruction in the fetal tissues and stimulating histopathological effects in them [22, 23, 24], since these free radicals cause the devastation of mother's tissues such as the uterus and placenta and what they contain of blood vessels which leads for a failure to reach the blood that provides oxygen as well as other nutrients to the cells as a result of necrosis and degeneration of the cells of these blood vessels and as an result the tissue cells are exposed to a lack of oxygen and nutrition necessary for cells to carry out their various functions and these promote harmful histological effects on body organs [24].

**TABLE 1.** Spasmine Effects on Embryos Liver Weights During the 19<sup>th</sup> Day of Gestation.

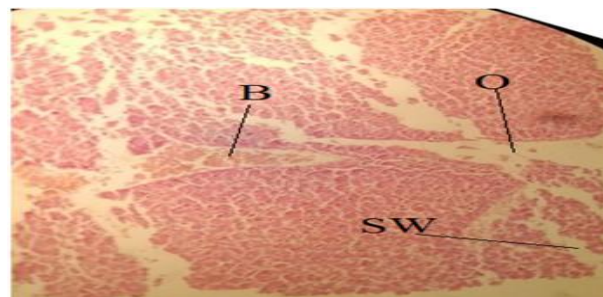
Treatments	weights (g) M±SE
Control Group (G1)	0.150 ± 0.002
Spasmin Drug Treated Group (G2)	0.071 ± 0.005
LeasSignificant Difference (LSD)	0.350

**TABLE 2.** Spasmine effects on pregnant Rats' liver weights during 19<sup>th</sup> day of gestation.

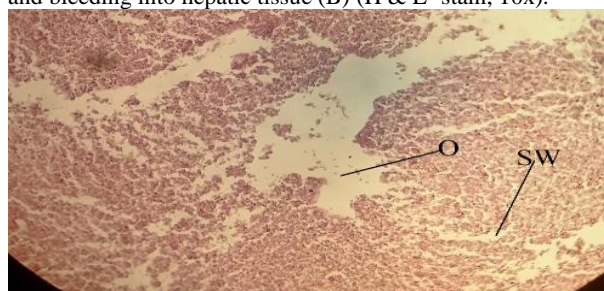
Treatments	weights (g) M±SE
Control Group (G1)	8.25±0.01
Spasmin Drug Treated Group (G2)	7.50±0.04
LeasSignificant Difference (LSD)	0.20



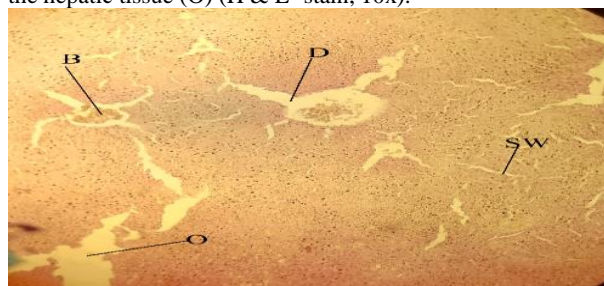
**Figure 1.** A Cross-section of liver tissue of a rat fetus from a control group: Hepatic tissue should have the following normal structure: Central vein (C), sinusoids (S) (H & E -stain, 10x).



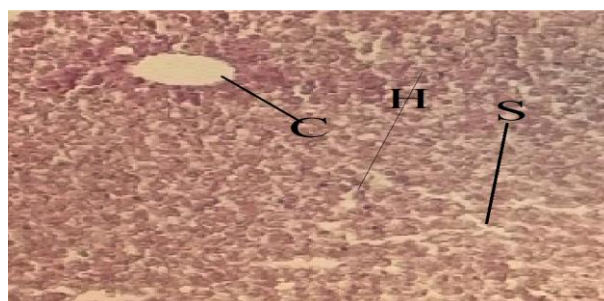
**Figure 2.** A Cross-section of liver tissue from a rat fetus from a dosed mother with spasmine. It shows: the following: Necrosis of hepatic tissue (O), expansion of sinusoids (Sw), and bleeding into hepatic tissue (B) (H & E -stain, 10x).



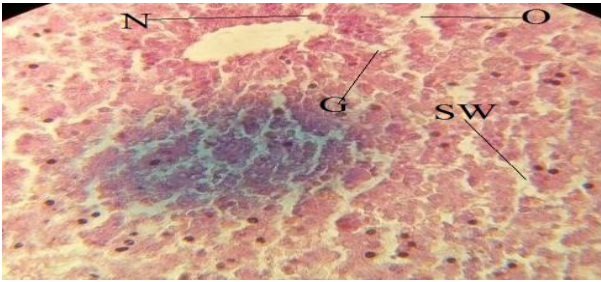
**Figure 3.** A Cross-section of liver tissue from a rat fetus from a dosed mother with spasmine: Expansion of the sinusoids (Sw), congestion into the hepatic tissue (B), and necrosis of the hepatic tissue (O) (H & E- stain, 10x).



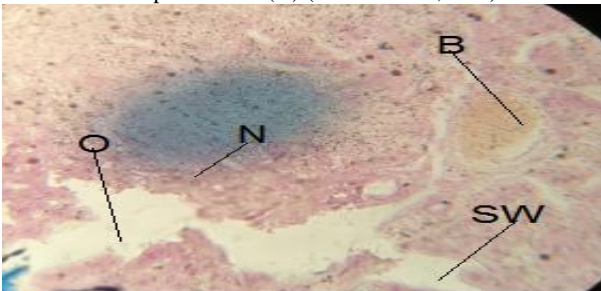
**Figure 4.** A Cross-section of liver tissue from a rat fetus from a dosed mother with spasmine: A breakdown in the fundamental architecture of the hepatic tissue, Widening of sinusoids (Sw) and necrosis of liver tissue (O) (H & E -stain, 10x).



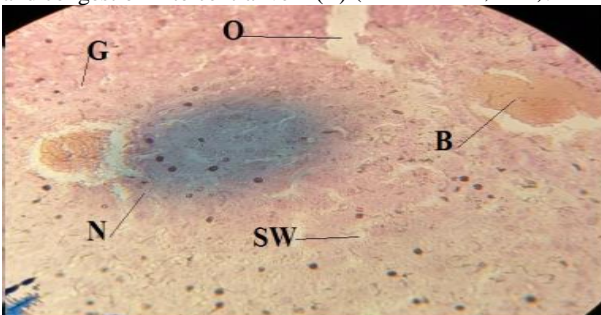
**Figure 5.** A Cross-section of liver tissue of a rat fetus from a control group :Normal structure of hepatic tissue, showing the central vein (C), sinusoids (S), and hepatic cells (H) (H & E-stain, 40X).



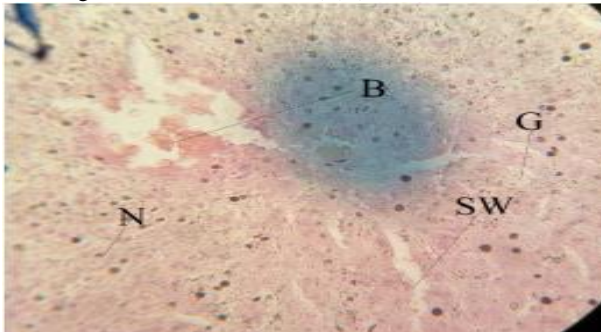
**Figure 6.** A Cross-section of liver tissue from a rat fetus from a dosed mother with spasmine: hepatocyte necrosis (N), hepatocyte degeneration (G), sinusoids expanding (SW), and necrosis into hepatic tissue (O) (H & E- stain, 40X).



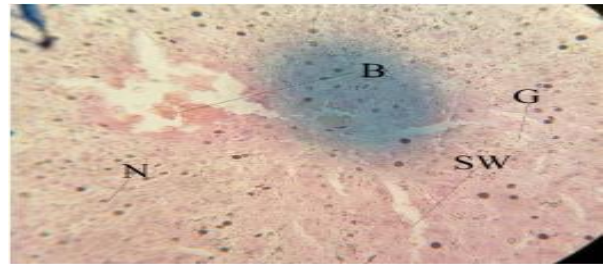
**Figure 7.** A Cross-section of liver tissue from a rat fetus from a dosed mother with spasmine: Hepatocyte necrosis (N), sinusoids broadening (SW), necrosis into hepatic tissue (O), and congestion into central vein (B) (H & E- stain, 40X).



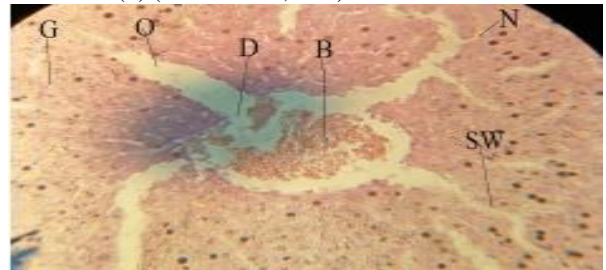
**Figure 8.** A Cross-section of liver tissue from a rat fetus from a dosed mother with spasmine :Hepatocyte necrosis (N), sinusoids broadening (SW), necrosis into hepatic tissue (O), and congestion into central vein (B) (H & E- stain, 40X).



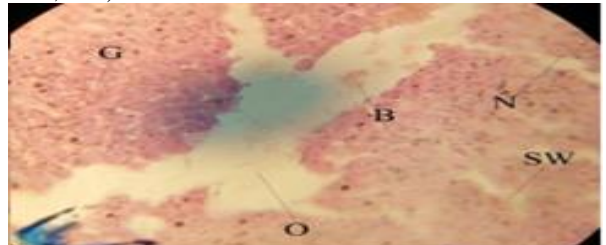
**Figure 9.** A Cross-section of liver tissue from a rat fetus from a dosed mother with spasmine: hepatocyte necrosis (N), hepatocyte degeneration (G), sinusoids expanding (SW), and congestion into the central vein (B) (H & E -stain, 40X).



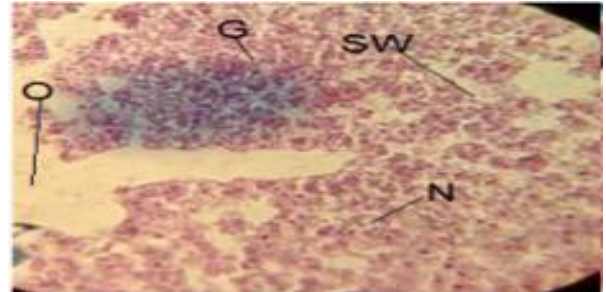
**Figure 10.** A Cross-section of liver tissue from a rat fetus from a dosed mother with spasmine: Hepatocyte necrosis (N), hepatocyte degeneration (G), sinusoids expanding (SW), necrosis into hepatic tissue (O), and inflammatory cell infiltration (F) (H & E- stain, 40X).



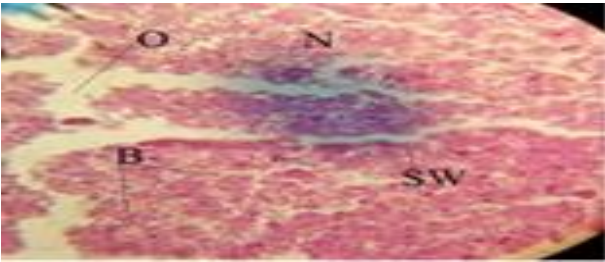
**Figure 11.** A Cross-section of liver tissue from a rat fetus from a dosed mother with spasmine: destruction of central vein wall (D), (N), hepatocyte degeneration (G), sinusoids hepatocyte necrosis widening (SW), necrosis into the hepatic tissue (O), and congestion into the central vein (B) (H & E- stain, 40X).



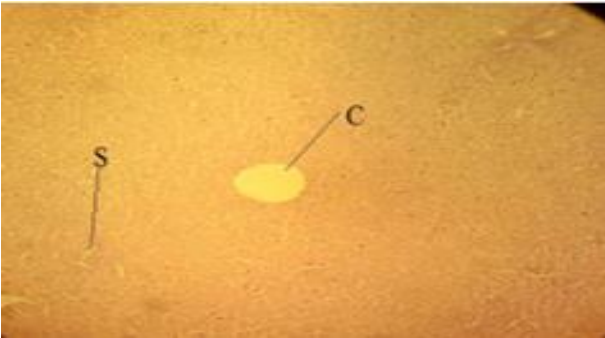**Figure 12 .** A Cross-section of liver tissue from from a dosed pregnant rat from dosed with spasmine: hepatocyte necrosis (N), hepatocyte degeneration (G), sinusoids expanding (SW), necrosis into hepatic tissue (O), and bleeding (B) (H & E- stain, 40X).



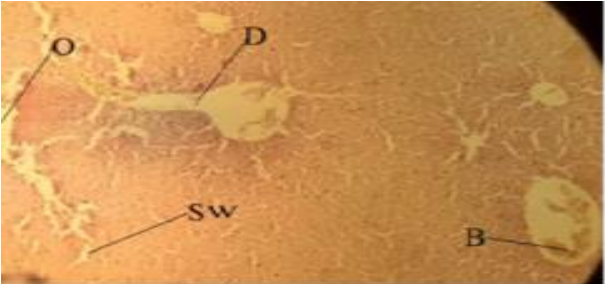
**Figure 13.** A Cross-section of liver tissue from from a dosed pregnant rat from dosed with spasmine :loss of the overall structure of the hepatic tissue.Necrosis into hepatic tissue (O), hepatocyte necrosis (N), hepatocyte degeneration (G), and sinusoids expanding (SW) (H & E -stain, 40x ).



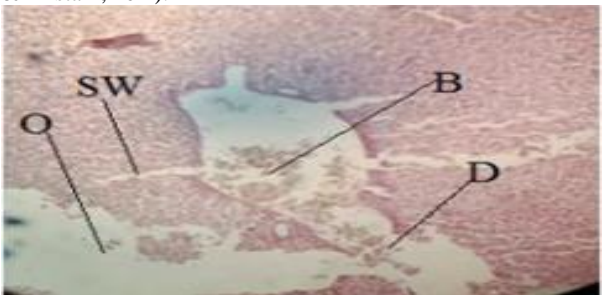
**Figure 14.** A Cross-section of liver tissue from from a dosed pregnant rat from dosed with spasmine: A breakdown in the fundamental architecture of the liver's tissue: Hepatocyte necrosis (N), sinusoids broadening (SW), necrosis into hepatic tissue (O), and bleeding into hepatic tissue (B) (H & E -stain, 40x).



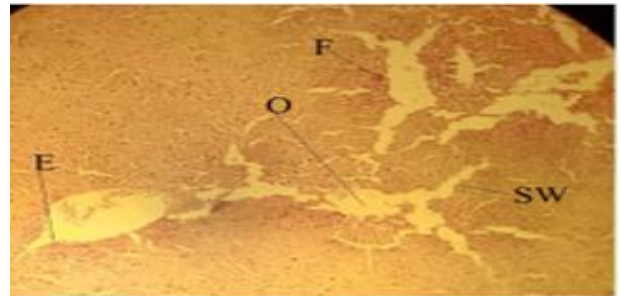
**Figure 15 .** A Cross-section of liver tissue of a rat fetus from a control group: Normal structure of hepatic tissue, showing sinusoids (S), central vein (C) (H & E -stain, 10x ).



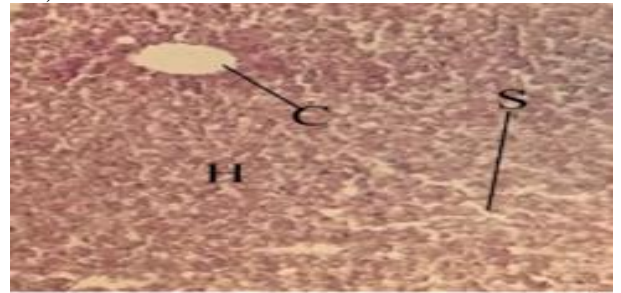
**Figure 16.** A Cross-section of liver tissue from from a dosed pregnant rat from dosed with spasmine :Destruction of the wall of the central vein (D), sinusoids widding (Sw), necrosis in hepatic tissue (O), and congestion in the central vein (B) (H & E -stain, 10x ).



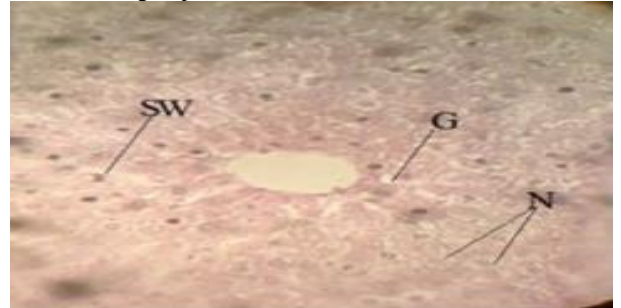
**Figure 17.** A Cross-section of liver tissue from from a dosed pregnant rat from dosed with spasmine: Inflammatory cell infiltration (F), necrosis in hepatic tissue (O), expansion of the central vein (E) (H & E -stain, 10x).



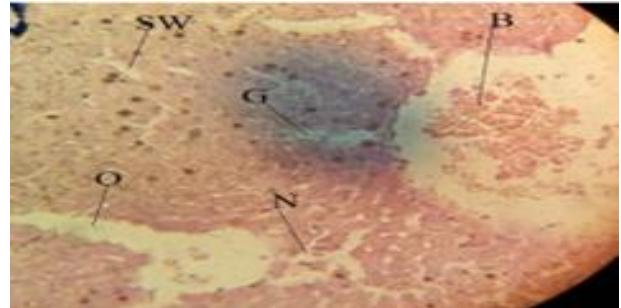
**Figure 18.** A Cross-section of liver tissue from from a dosed pregnant rat from dosed with spasmine :Congestion in the central vein (B) as a result of necrosis in the hepatic tissue (O) and destruction of the central vein wall (D) (H & E- stain, 10x).



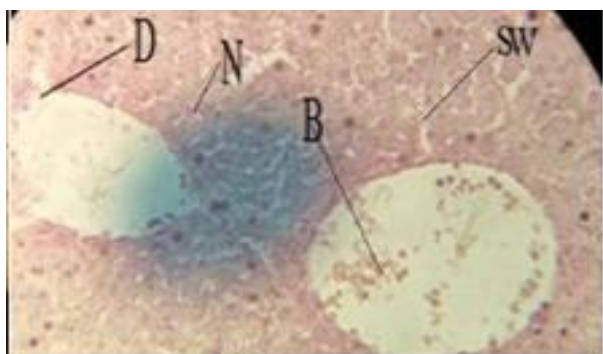
**Figure 19.** A Cross-section of liver tissue of a rat fetus from a control group: (H), central vein (C), sinusoids (S), and hepatic cells (H) are all visible in this cross slice of pregnant rat liver from control group (H & E -stain, 40X).



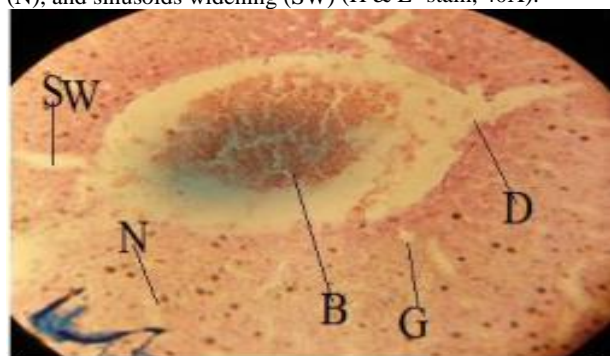
**Figure 20.** A Cross-section of liver tissue from from a dosed pregnant rat from dosed with spasmine: Hepatocyte necrosis (N), hepatocyte degeneration (G), and sinusoids broadening (SW) (H & E -stain, 40X).



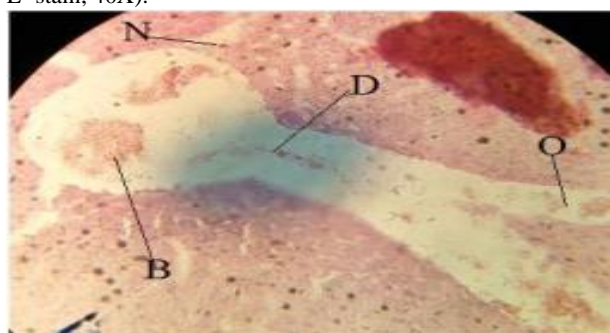
**Figure 21.** A Cross-section of liver tissue from from a dosed pregnant rat from dosed with spasmine :hepatocyte necrosis (N), destruction of central vein (D), sinusoids expanding (SW), and congestion into the central vein (B) (H & E -stain, 40X).



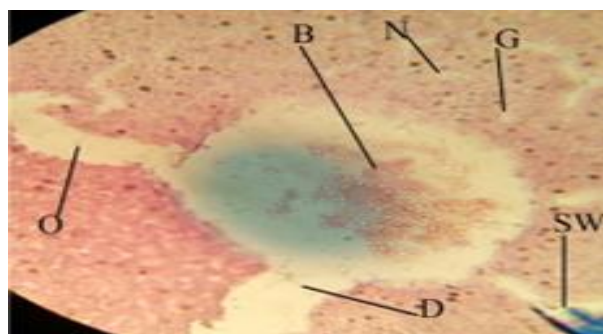
**Figure 22.** A Cross-section of liver tissue from from a dosed pregnant rat from dosed with spasmine:Necrosis into hepatic tissue (O), congestion in the central vein (B), Hepatocyte necrosis (N), sinusoids widening (SW), hepatocyte necrosis (N), and sinusoids widening (SW) (H & E -stain, 40X).



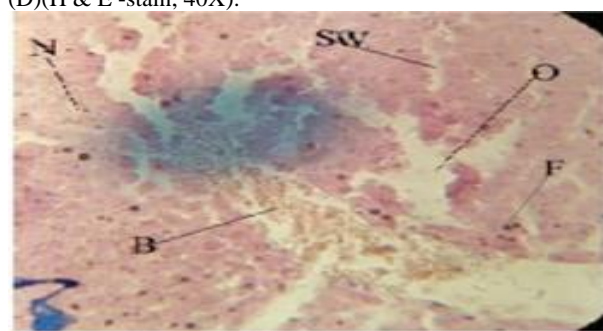
**Figure 23.** A Cross-section of liver tissue from from a dosed pregnant rat from dosed with spasmine: destruction of the wall of the central vein (D),Necrosis of hepatocytes (N), necrosis of hepatic tissue (O), and congestion in the central vein (B) (H & E -stain, 40X).



**Figure 24.**A Cross-section of liver tissue from from a dosed pregnant rat from dosed with spasmine:Abnormalities hepatocyte necrosis (N), hepatocyte degeneration (G), sinusoids broadening (SW), and congestion into the central vein (B) (H & E -stain, 40X).



**Figure 25.** A Cross-section of liver tissue from from a dosed pregnant rat from dosed with spasmine :Expansion and destruction of the central vein wall (D), hepatocyte necrosis (N), hepatocyte degeneration (G), necrosis into hepatic tissue (O), sinusoids expanding (SW), and congestion into hepatic vessels (B) ,Expansion and destruction of the central vein wall (D)(H & E -stain, 40X).



**Figure 26.** A Cross-section of liver tissue from from a dosed pregnant rat from dosed with spasmine :Hepatocyte necrosis (N), necrosis into hepatic tissue (O), sinusoids expanding (SW), congestion into hepatic vessel (B) (B), and inflammatory cell infiltration (F) )(H & E -stain, 40X).

#### 4. REFERENCES

1. Umpierrez,E.; Chung,H.; Chung,H. ; Iversen,L.; Lim,W. and Lee,JOURNAL OF Terminology and Information on Drugs. UNODC.ISBN,(2016), 921-978.
2. Abdulhady,S.S. and Ibrahim, K. M HPreparation and evaluation of mebeverine hydrochloride asmucoadhesivebuccal tablet for local anesthesia. TROPICAL JOURNAL. PHARMACOLOGY RESEARCH. 16 (8) ,(2017), 1805-1812.
3. Ford, J. A. Non-medical Prescription drug Use and Delinquency: An analysis with a national sample. DRUGS.38(2) ,(2008),493-516.
4. Stankovic , I. N.and Colak,D. Prenatal Drugs and Their Effects on the Developing Brain: Insights From Three-Dimensional Human Organoids.FRONTIERS. NEUROSEIENCE. (2022), <https://doi.org/10.3389/fnins.2022.848648>.
5. Champer ,C.H . and Scialli ,A.R. Teratogenesis and Environmental Exposur ,in : Creasy and ResnikMatemal-Fetal medicine by Resnik, R.; Greene, M. F. ;Lams ,J.D.; Lockwood , Ch .J.; Moore Th. R., seven edition . Elsevier Saunders ,Philadelphia. (2014) ,
6. Annahazi, A.; Roka, R.;Rosztoczy, A. and Wittmann, T.Role of antispasmodics in the treatment of irritable bowel syndrome. WORLD JOURNAL



- GASTROENTEROLOGY. 20 (20), (2014),6031–6043.
7. Daniluk ,J.; Malecka-Wojcieszko ,E.; Skrzydło-Radomska ,B. and Rydzewska ,G.The Efficacy of Mebeverine in the Treatment of Irritable Bowel Syndrome—A Systematic Review. JOURNAL CLINICAL MEDICINE. 11, (2022), 1044.
  8. Ensslin, H.K. ; Maurer, H.H. .; Gouzoulis, E. ; Hermle, L. and Kovar. K.A. Metabolism of racemic 3,4-methylenedioxyethylamphetamine in humans, isolation, identification, quantification, and synthesis of renal metabolites. Drug Metabolism and Disposition.24, (1996) ,813-820.
  9. Abdel-Hamid ,S.M.; Abdel-Hady, S.E.; El-Shamy, A.H. and El-Dessouky ,H.F.A novel formulation for mebeverine hydrochloride. Drug Development and Industrial Pharmacy . 33, (2007), 1078-1089.
  10. Hatami, K.; Kazemi-Motlagh, A.H.; Ajdarkosh, H.; Zargarani, A.; Karimi, M.; Shamshiri, A.R.; Ghadir, M.R. Comparing the Efficacy of Cumin Sofouf With Mebeverine on Irritable Bowel Syndrome Severity and Quality of Life: A Double-blind Randomized Clinical Trial. Crescent .JOURNAL MEDICINE BIOLOGY SEIENCE. 7, (2020),186–194.
  11. Gilbody, J.S.; Fletcher, C.P.; Hughes, I.W.; Kidman, S.P. Comparison of two different formulations of mebeverine hydrochloride in irritable bowel syndrome. INRTNATIONAL JOURNAL CLINICAL PRACTIE. 54, (2000),461–464.
  12. Rahman, M. Z.; ahmed , D. S.; Mujib , B. S.; Mahmuduzzaman, M. and Rahman, M A. Comparative safety and efficacy of trimebutine versus mebeverine in the treatment of irritable bowel syndrome. MYMENSINGH MEDICAL JOURNAL. 23(1),(2014), 105-113.
  13. Elliott ,S. and Burgess ,V.Investigative implications of the instability and metabolism of mebeverine. JOURNAL OF ANATOMICAL TOXICOLOGY. 30,(2006) ,91-97.
  14. Hafez,E.S. Reproductive and breeding technique for laboratory animals.Lead Febiger,Philadelphia,U.S.A , (1970),305-313.
  15. Suvarna,S.K.;Lyaton,C. and Bancroft,J.D.Bancrofts theory and practice of histological technique.7ed .Elsevier.Limited . , China.Xiv, (2013), 604.
  16. Morgan,G.A.;LeechN.A.;Gloecner,G.W. and Barrett, K.C.SPSS for introductory statistic:use a introduction .2nd ed.Lawrenz Erlbaum association publishers Mahwash,New Jersey. London.(2010),
  17. Plmieri, C.and Conger, R.Teratogenic Potential of the newer antiepilepticdrugs. CNS DRUGS. 16(11), (2002), 755-764 .
  18. Ozsurekci,Y. and Aykac,K.Oxidative stress related diseases in newborns. JOURNAL OF OXIDATIVE .MEDCINE CELL LONGEVITY, (2016),9.
  19. Amiri,M.Oxidative stress and free radicals in liver and kidney diseases ;an updated short-review. JOURNAL OF NEPHROPATHOLOGY. 3(7/3),(2018),127-131.
  20. Freeman, B.A. and Crapo, J. D.Free Radicals and Tissue Injury. Laboratory .Investigation. 47(5), (1982), 412-426.
  21. Haroun, H.S. Terdtogenicity and teratogenic factors. Mo. JOURNAL ANATOMY AND PHSYSIOLOGY.3(1), (2017),1-8 .
  22. Al-Naemi, R.S.; Ab. Dullah, Q.H. and Ibrahim, S.A. Impactof oxidativ stress on pregnancy outcome in albino rats. IRAQI JOURNAL OF VERTERNARY SEIENNCE .26(2), (2012), 93-99.
  23. Elshama, S.; Abdalla,M.E. and Mohamed, A.M.Role of natural antioxidant treatment of toxicity. JOURNAL OF TOXICOLOGICAL ANALYSIS. 1(1), (2018),3.

#### Arabic Abstract

أجريت الدراسة لتحديد دور عقار السبازامين في بعض المعايير الوزنية و النسجية لأكياد إناث الجرذان الحوامل وأجنتها في اليوم التاسع عشر من الحمل. أجريت الدراسة في كلية التربية للبنات في جامعة الكوفة للمدة من 1 كانون الثاني 2022 ولغاية 15 حزيران 2022. وبعد الحصول على 8 من الجرذان الحوامل تم تجريع 4 منهم بجرعة من المحلول الفسيولوجي وقد مثلت هذه المجموعة السيطرة (G1) بينما 4 من إناث الجرذان الحوامل جرعت عقار السبازامين بجرعة (0.48 ملغم/كغم/وزن الجسم) (G2) لمدة 19 يوماً، وكانت الجرذان الحوامل في المجموعة السيطرة بعمر (12) أسبوع ووزن (231) غرام بينما كانت الحيوانات الحوامل في المجموعة المعاملة بعقار السبازامين بعمر (11) اسبوع ووزن (230) جرام.

سجلت نتائج الدراسة انخفاضاً معنوياً ( $P < 0.05$ ) في أوزان الكبد لكل من الحيوانات الحامل وأجنتها في مجاميع الجرذان المعالجة بعقار السبازامين ، كما أظهرت النتائج أن معاملة الجرذان بعقار السبازامين حتى اليوم التاسع عشر من الحمل أدى إلى تغيرات مرضية وغير طبيعية في أنسجة الكبد مثل تلف جدار الوريد المركزي، نخر خلايا الكبد، توسع الجيبانيات، تنخر الأنسجة الكبدية وارتشاح الخلايا الالتهابية في الجرذان الحوامل وأجنتها مقارنة بالجرذان الحوامل وأجنتها في مجموعات السيطرة أثناء الحمل في اليوم التاسع عشر.

الاستنتاج: إن العلاج بعقار التشنج أدى إلى انخفاض وزن الحوامل وكبد الأجنة كما أحدث تغيرات نسجية مرضية مختلفة في بنية أكباد الجرذان الحوامل وأجنتها خلال اليوم التاسع عشر من الحمل.