



Evaluation the efficacy of *Leea indica* leaves aqueous extract against nephrotoxicity induced by Diethylnitrosamine (DEN) in male rats

Mustafa Abd-Alhussein Kazam* and Heba A. Abd-Alsalam Alsalame

Biology Department, Education for Pure Sciences College, University of Kerbala, Kerbala, Iraq

*Corresponding author e-mail: Email: m03161167@s.uokerbala.edu.iq

<https://doi.org/10.59658/jkas.v10i3.1246>

Received: Aug. 7, 2023	Abstract The aim of this study is to find out the quality of the aqueous extract of <i>leea indica</i> leaves in protecting kidney tissues from oxidative stress caused by DEN. Forty adult males were randomly assigned in four equal sets (ten animals per set), the (G1) They were given 1 ml of normal water, a control set was returned, and the G2 given 200 mg/kg of DEN two days, while the G3 given 60 mg/kg of <i>leea indica</i> leaves, while the animals of the given G4 200 mg/kg of DEN. And 60 mg/kg of <i>L.indica</i> extract. FINDINGS When the albino rat was dosed with <i>leea indica</i> aqueous extract, the kidney damage induced by DEN was significantly decreased. The extract worked to mitigate kidney damage caused by DEN, which was demonstrated in histological examination by atrophy of the renal glomerulus and shrinkage of the glomerulus. Urinary tubules break down with hemorrhage. We conclude from the current study that the aqueous extract of the leaves of the bandicoot berries contributed to the reduction of hepatotoxicity induced by diethyl nitrosamine.
Accepted: Aug. 30, 2023	
Published: Sept. 10, 2023	
Key words: diethylnitrosamine, <i>leea indica</i> , Antioxidants, kidney	

Introduction

The kidney is an important organ in the body that is shaped like a bean, and is located in the abdominal cavity on both sides of the spine under the diaphragm, and the left kidney is at a higher level than the right kidney, and the kidney receives approximately 25% of the cardiac output, as the percentage of blood entering the kidney is in the region The cortex is about 85%, the outer medulla is about 14%, and the inner medulla is about 1% [1]. The nephron represents the functional unit of the kidney, and one kidney consists of about one million nephrons and involves approximately 40 different types of cells [2]. The basic function of the kidney is achieved through four main processes: Glomerular filtration (GF), Reabsorption, Secretion, and Excretion [3,4]. as it works to purify the blood from waste products. With the glomerular filtration process, this function can be preserved even after losing half of the number of renal nephrons, and this is the reason why a healthy person can donate his kidney to lose 50% of the renal nephrons and maintain the normal glomerular filtration rate [5] as The kidneys perform many important functions in the body, the most prominent of

which are maintaining the acid and alkaline balance, electrolyte balance, osmosis, removing harmful waste and maintaining the regulation of water in the body, furthermore secreting the hormone erythropoietin and cholesterol, and the kidney is one of the organs most vulnerable to toxic substances resulting from Medicines since the large volume of blood coming to them from the heart [6] *Leea indica* bandicoot berries have wide medical importance all over the world, as they are used to treat many health disorders. They have been used as a treatment for many skin problems, fever, joint pain and dizziness, furthermore being used to treat digestive disorders such as diarrhea and stomach ulcers [7,8], and it possesses anti-cancer, anti-microbial, antidiabetic, liver, vascular and central nervous system disorders, as well as used as a treatment for rheumatism, fractures, wounds, dysentery and sexual disorders [9], as well as the use of this plant to treat viral infections and some types of cancers Being one of the plants rich in antioxidants [10] as the leaves of this plant contain hydrocarbons, palmitic acid, phthalate derivatives, gallic acid, solanesol, phytosterols, and triterpenes, And catechins, tannins, flavonoids, coumarins, megastigmanes, and oxylipins. [11,12], and other studies demonstrated that the leaves of these plants contain other chemical components such as alkaloids, lignins, saponins, sterols, and anthraquinones [13] Diethylnitrosamine (DEN) is a yellow liquid organic chemical compound. It is considered a mutagenic and carcinogenic substance. It is classified as a nitrosamine with a chemical formula $C_4H_{10}N_2O$. It has a boiling point of 177 degrees Celsius (351 F), a density of 0.95 grams / ml, and a molar mass of 102.14 grams / mol [14] It is a harmful pollutant that is widely found in many foodstuffs including salted fish, alcoholic beverages, milk, processed meat products, and many vegetables [15]. In addition, it is present in tobacco smoke, cosmetics, agricultural chemicals, pharmaceutical drugs, and contaminated water. [16] Subject to food and environmental pollutants poses a significant risk to human and animal health. The harmful effects of DEN have been demonstrated to be increased production of free radicals, inflammation, and DNA damage. [17] It has been proven that DEN has carcinogenic effects on mice, hamsters, rats, guinea pigs, and rabbits, furthermore its carcinogenic effects on humans. Thus, DEN is widely used as an experimental carcinogen [18] Various nitrosamines are among the substances that cause acute hepatotoxicity and carcinogens in many types of animals, involving DEN. Which is given orally or by injection in experiments conducted on most rodents in high and effective doses for the purpose of inducing kidney tumors [19] DEN is primarily metabolized in the liver to its harmful metabolite, N-acetyl-p benzoquinoneimine, by cytochrome P450 [20] and particularly Cytochrom 2E1 enzymes, resulting in alkyl set-containing metabolites that have The ability to cause DNA damage, promote programmed cell death, and eventually lead to injury to the kidneys and many other organs, involving the liver[21,17]. The aim of the current study was to find out the protective role of Panicot berry leaves against nephrotoxicity resulting from diethylnitrosamine.

Materials and Methods

A total of 40 rats were used, divided into 4 groups (10 animals / set): the first set took a dose of 1 ml of plain water and is considered a control set, and the 2nd set was injected with DEN at a concentration of 200 mg / kg, while the 3rd set was given a daily dose of 60 mg / kg of Aqueous extract of bandicoot berries leaves, the IV set injected 200mg/kg of DEN + 60mg/kg of aqueous bandicoot berry extract.

Anatomy and take tissue samples

Animals were placed in a tightly closed transparent box after being given a chloroform-coated cotton swab to use for anesthesia. All rats from all sets were anesthetized and animals were dissected and these organs were cut into small pieces and preserved longitudinally and transversely and placed in 10% formalin for at least 48 hours. These samples were then dehydrated with ascending alcohol concentrations. After being cleaned with xylene, they were combined with paraffin wax at 56 °C to form blocks. All tissue sections were then stained with hematoxylin-eosin after placing the blocks and sections in a rotary microtome at 5 µm [22].

Preparation of the aqueous extract

A quantity of 20g of dry powder was used and subsequently combined with 400 milliliters of distilled water. The mixture was subjected to an electric grinder and allowed to stand at ambient temp for a duration of 24 hours. The mixture was subjected to filtration utilizing multiple layers of medical gauze, followed by centrifugation at a velocity of 3000 revolutions per minute. The solution was subjected to filtration utilizing filter paper for a duration of 10 minutes to achieve a clarified state. The extract was subjected to drying utilizing an electric oven at a temp of 40 degrees Celsius, and subsequently stored in a refrigerated environment until further use, as reported by [23].

The aforementioned technique was utilized to produce the *Leea indica* extract, albeit with certain alterations, outlined as follows: The desiccated foliage was pulverized utilizing an electric pulverizer and immersed in distilled water for a duration of 24 hours with continuous agitation. The resultant mixture was then filtered through multiple layers of medical gauze and soft, uncontaminated cloth. The filtrate was subsequently transferred to sanitized glassware and subjected to air drying via fan. The extract was then refrigerated until its intended use.

Results and discussion

The histological study demonstrated that the histological sections of the kidney of laboratory rats in the control groups, Figure (1).

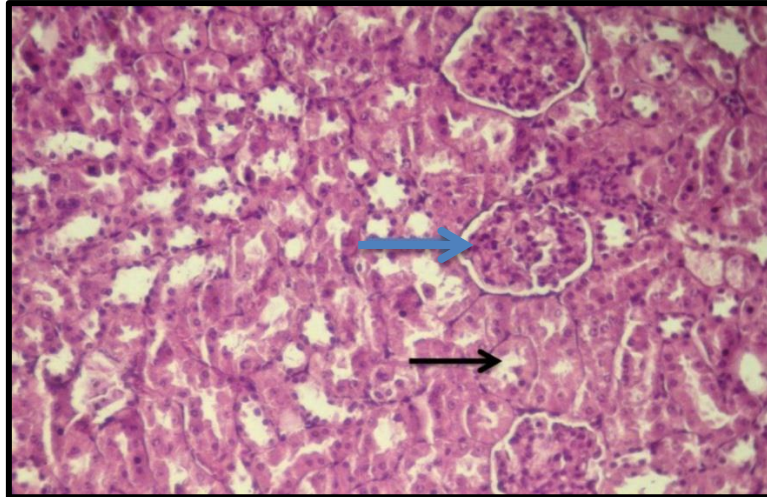


Figure (1): Kidney section from rat (control) demonstrating normal appearance of glomerulus (blue arrow), urinary tubules (black arrow). (H&E 200X)

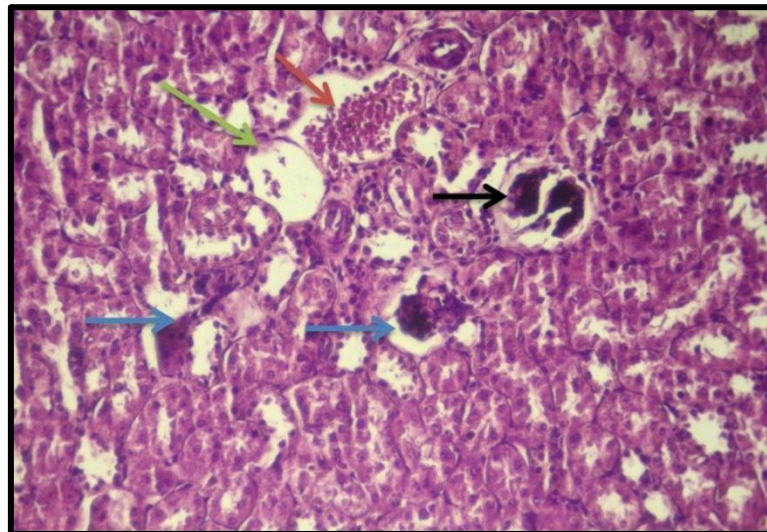


Figure (2): The effect of oral dose of 200 mg / kg of DEN for a period of three months to white male rats, , was demonstrated on the kidney tissue, as the urinary glomerulus shrinkage (blue arrow) and contraction in the glomerulus (black arrow) furthermore the destruction of the urinary tubules (green arrow) with hemorrhage (red arrow) (H&E 200X).

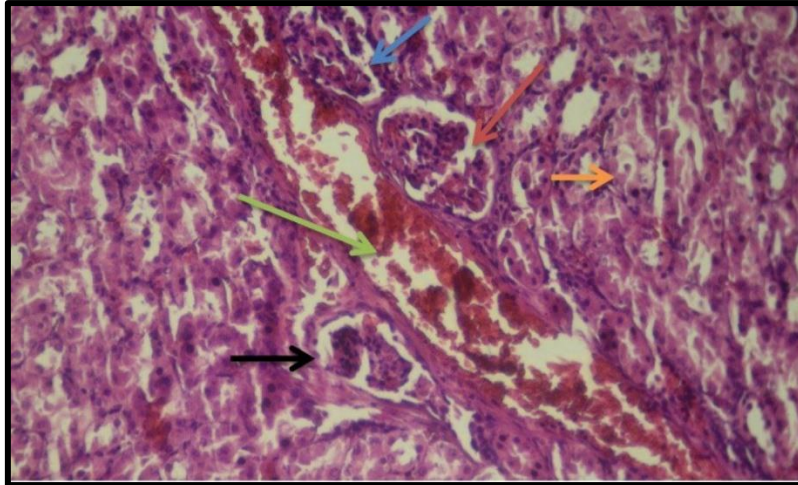
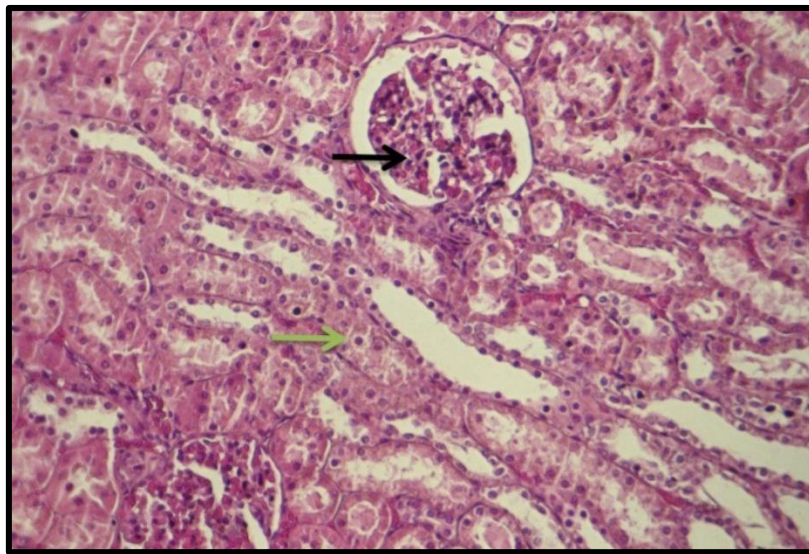


Figure (3): The effect of oral dose of 200 mg / kg of DEN for three months in male white rats was demonstrated, on the kidney tissue, as atrophy of the urinary glomerulus (black arrow) and shrinkage of the glomerulus (blue arrow) was observed, furthermore the breakdown of the urinary tubules (Orange arrow) with hemorrhage (green arrow) furthermore an increase in Bowman's space (red arrow) , by hematoxylin and eosin 200 H&E stain



Figure(4): The effect of an oral dose of (60 mg / kg) of aqueous extract of leea indica leaves on the kidney tissue of white male rats for a period of three months, stained with hematoxylin and eosin (H&E 200X), noting the normal structure of the glomerulus (black arrow) and the urinary tubules (green arrow) in kidney tissue

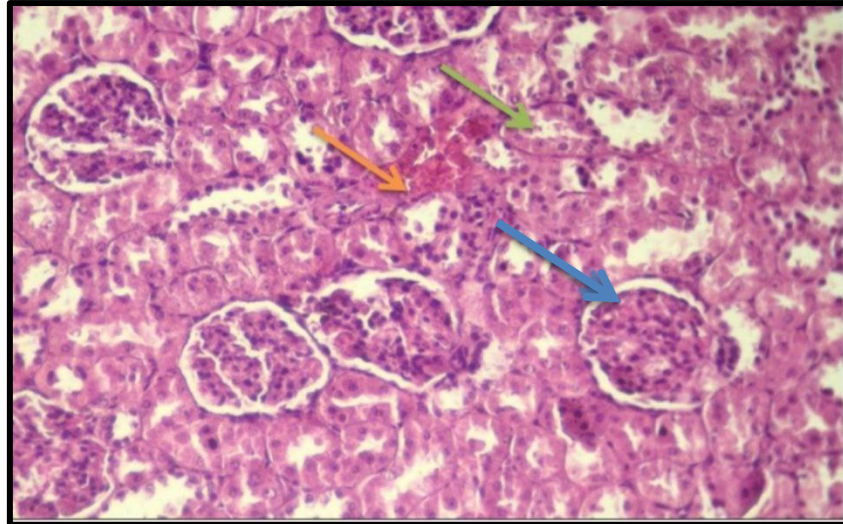


Figure (5): The effect of an oral dose of 200 mg/kg of DEN was demonstrated with an apical dose of 60 mg/kg of German extract of leea indica leaves for three months,. The normal structure of the glomerulus (blue arrow) and urinary tubules (green arrow) was noted with hyperemia (orange arrow). by hematoxylin and eosin stain (200 H&E)

Effect of diethyl nitrosamine treatment on kidney tissue

The findings of histopathology demonstrated that injection into the peritoneum with DEN led to congestion, atrophy, and shrinkage of the urinary glomerulus, furthermore an increase in Bowman's space, destruction of the urinary tubules, and sloughing of the inner lining of the urinary tubules. This is consistent with [24,25] The harmful renal effects that have occurred may be the result of subject to various exotic substances or medicines and toxins and the incitement of oxidative stress, and this may follow the activation of various factors and paths that participate in kidney tissue damage and increase the production of inflammatory cytokines, and these changes can lead to an imbalance between these The inflammatory factors and antioxidant defense systems of the cell, which ultimately leads to defrauding tissue disturbances and changes [26] The body subject to the substance of the DEN led to the effect of the kidneys and its tissues significantly as a result of the toxicity that occurs, and it occurs that the kidney injury is also related to the liver, given that the kidneys also participate in the DEN metabolism in the body, where the metabolism of the DEN occurs in the liver through the cytochrome system P450 It has become clear that generating the types of interactive oxygen ROS excessively causes kidney tissue damage by strengthening a peroxidized fat and damaging cellular membranes, DNA and cellular proteins, as ROS causes an exhaustion of the antioxidant system, and the college is one of the most vulnerable organs to damage by many of the malware This may be since the availability of long-term multiple sebaceous fatty acids in the formation of renal fats and perhaps the tendon damage in the kidney is attributed to the activity of the stimulating infections such as the $tnf-A$ $tnf-A$ Secretion [27,28] It was also found that DEN decreases the activities of brush border membrane enzymes, increases lipid oxidation, protein

oxidation, and increases hydrogen peroxide levels, thus destroying the cellular membranes of urinary tubules and glomeruli [29].

Effect of treatment with aqueous extract of *leea indica* leaves on kidney tissue

The present study's findings demonstrate that the leaves of *Leea indica* and its active compounds exhibit a beneficial effect on renal cell damage, renal filtration rate, and the functions and structure of glomeruli and renal tubules. Oxidative stress is known to result in a reduction of antioxidants, while the application of bandicoot berry botanical extract has been found to mitigate oxidative damage and safeguard kidney function by enhancing the antioxidant system. According to [10,30] the enhancement of kidney tissue can be attributed to the active flavonoids found in the aqueous extract of the leaves. These flavonoids possess antioxidant properties, enabling them to donate hydrogen atoms to free radicals and mitigate their detrimental effects on the tissue. Consequently, this process decreases lipid peroxidation, safeguards cellular membranes against oxidative harm, and augments the tissue's repair system. Cellular damage [31] The reason for the improvement in the kidney tissue can be attributed to the fact that the bandicoot berry plant contains ascorbic acid, which works to protect cells from damage, as it is a catalyst for many enzymatic reactions, involving 2-oxoglutarate-dependent dioxygenase, which is important for the work and regulation of the embryonic structure of cells, through Stimulation of hydroxylation of nucleic acids DNA, RNA, as well as ascorbic acid maintains the stability of cells by protecting them from free radicals, by donating electrons to unstable molecules and converting them into stable molecules, decreases inflammation and repairs damaged tissues [32,33] The reason for the improvement in the kidney tissue may be since the fact that the aqueous extract of the plant contains megastigmanes, which has an important role in improving kidney function represented by decreasing levels of urea and creatinine in the blood, as well as increasing albumin levels and improving bilirubin, which leads to preventing the accumulation of more proteins in the tissues of the kidneys to decrease From renal damage, this findings in decreasing necrosis, congestion, and hemorrhage in the renal tissue, as well as decreasing glomeruli hyperplasia [34] It can be attributed to the preventive role of the raspberry leaves extract because it contains many active substances such as phenols and polyphenols that have the ability to sweep free radicals. The activity of the components of the antioxidant extract mainly since the properties of their oxidation and reduction. Breaking the series of free radicals by donating the hydrogen molecule and leads to the oxidation of the free root and its transformation into a stable condition, as a result of its external cover with electrons or the maintenance of the balance of antioxidants and the reduction of cancerous tumors resulting from the interactive oxygen types by visiting the super -desecotes activity (SOD) and glutathione (GSH) Also, by decreasing fat peroxide, gallic acid also stops the cell cycle, self -accumulation, and programmed cell death by stimulating the caspase path and working to regulate the proteins associated with the cell cycle such as Cyclin A, Cyclin D1



and Cyclin E, and delay the division of the unjust cell. By inciting the P27KIP enzyme and discharged CDK activity [35,36].

References

- 1) Radi, Z. A. (2019). Kidney pathophysiology, toxicology, and drug- induced injury in drug development. *International journal of toxicology*, 38(3): 215-227.
- 2) Lake, B. B.; Chen, S.; Hoshi, M.; Plongthongkum, N.; Salamon, D.; Knoten, A.; Vijayan, A.; Venkatesh, R.; Kim, E.; Gao, D.; Gaut, J.; Zhang, K. and Jain, S. (2019). A single-nucleus RNA- sequencing pipeline to decipher the molecular anatomy and pathophysiology of human kidneys. *Nature communications*, 10(1): 1-15.
- 3) Park, J.; Shrestha, R.; Qiu, C.; Kondo, A.; Huang, S.; Werth, M.; Li, M.; Barasch, J. and Suszták, K. (2018). Single-cell transcriptomics of the mouse kidney reveals potential cellular targets of kidney disease. *Science*, 360(6390): 758-763.
- 4) Alelign, T. and Petros, B. (2018). Kidney stone disease: an update on current concepts. *Advances in urology*, 1(1): 1-12.
- 5) Kramer, H. (2019). Diet and chronic kidney disease. *Advances in Nutrition*, 10(Supplement_4): S367-S379.
- 6) Chamanza, R.; Naylor, S. W.; Carreira, V.; Amuzie, C.; Ma, J. Y.; Bradley, A. E. and Loudon, C. (2019). Normal anatomy, histology, and spontaneous pathology of the kidney, and selected renal biomarker reference ranges in the cynomolgus monkey. *Toxicologic pathology*, 47(5): 612-633.
- 7) Daryaganj, A.R. (2019). *Alternative Therapy Health Series Herbal Cure*. V&Sublshers. Regional Office Hyderabad, India.
- 8) Deepa, M. R.; Udayan, P. S. and Anilkumar, K. A. (2017). Taxonomical and phytosociological studies on Chithalikavu-A sacred grove, Thrissur district, Kerala. *Tropical Plant Research*, 4(1): 20-30.
- 9) Hossain F.; Mostofa Md. G. and Alam AHM K. (2021) . Traditional uses and pharmacological activities of the genus *Leea* and its phytochemicals: A review . *Heliyon* , 7 : 1-12.
- 10) Khuniad C. , Nahar L.; Ritchie K. J. and Sarker S. D. (2022). Therapeutic Potential of *Leea indica* (Vitaceae). *Journal of Natural Products Discovery*. 1(1):1-20.
- 11) Wong, Y. H.; Abdul Kadir, H. and Ling, S. K. (2012). Bioassay-guided isolation of cytotoxic cycloartane triterpenoid glycosides from the traditionally used medicinal plant *Leea indica*. *Evidence-Based Complementary and Alternative Medicine*, 2012.
- 12) Srinivasan, G.; Ranjith, C. and Vijayan, K. (2008). Identification of chemical compounds from the leaves of. *Acta Pharmaceutica*, 58(2): 207-214.



- 13) Ghagane, S. C.; Puranik, S. I.; Kumbar, V. M.; Nerli, R. B.; Jalalpure, S. S.; Hiremath, M. B. and Aladakatti, R. (2017). In vitro antioxidant and anticancer activity of *Leea indica* leaf extracts on human prostate cancer cell lines. *Integrative medicine research*, 6(1): 79-87.
- 14) Verna, L.; Whysner, J. and Williams, G. M. (1996). N-nitrosodiethylamine mechanistic data and risk assessment: bioactivation, DNA-adduct formation, mutagenicity, and tumor initiation. *Pharmacology & therapeutics*, 71(1-2): 57-81.
- 15) Park, J. E.; Seo, J. E.; Lee, J. Y. and Kwon, H. (2015). Distribution of seven N-nitrosamines in food. *Toxicological research*, 31(3): 279-288.
- 16) Norwood, D. L.; Mullis, J. O.; Feinberg, T. N. and Davis, L. K. (2009). N-nitrosamines as "special case" leachables in a metered dose inhaler drug product. *PDA Journal of Pharmaceutical Science and Technology*, 63(4): 307-321
- 17) Owumi, S. E.; Aliyu-Banjo, N. O. and Danso, O. F. (2019). Fluoride and diethylnitrosamine co-subject enhances oxido-inflammatory responses and caspase-3 activation in liver and kidney of adult rats. *Journal of Biochemical and Molecular Toxicology*, 33(7): e22327.
- 18) Tae M K.; Tae J S.; Kyoung M Y.; Jin S K. and Dae J K. (2011): "The possibility of liver and lung carcinogenesis induced by diethylnitrosamine in newborn B6C3F1 mice". *Journal of Biomedical Research*. 12(2) : 81-89.
- 19) Emre, K. A. Y. A.; Yilmaz, S.; ÇERİBAŞI, A. O. and Selda, T. E. L. O. (2018). Protective effect of lycopene on diethylnitrosamine-induced oxidative stress and catalase expression in rats. *Ankara Üniversitesi Veteriner Fakültesi Dergisi*, 66(1): 43-52.
- 20) Ding, Y. F.; Wu, Z. H.; Wei, Y. J.; Shu, L. and Peng, Y. R. (2017). Hepatic inflammation-fibrosis-cancer axis in the rat hepatocellular carcinoma induced by diethylnitrosamine. *Journal of Cancer Research and Clinical Oncology*, 143(5): 821-834.
- 21) Li, M.; Lu, Y.; Li, Y.; Tong, L.; Gu, X. C.; Meng, J. and Tong, X. (2019). Transketolase deficiency protects the liver from DNA damage by increasing levels of ribose 5-phosphate and nucleotides. *Cancer research*, 79(14): 3689-3701.
- 22) Alsalam, H. A. A. A. (2020). Study Effects of *Nigella Sativa* Seeds Oil in Some Physiological Parameters in Experimental Heart Failure Induced by Ivabradine in Male Rats. *Indian Journal of Forensic Medicine & Toxicology*, 14(3): 2609-2613.
- 23) Mehany, A. B.; Farrag, I. M.; Diab, M.; Ghoneim, M. M.; El-Sherbiny, M.; Al-Serwi, R. H. and Abdelhady, A. A. (2023). Curcumin and vitamin C improve immunity of kidney via gene expression against diethyl nitrosamine induced nephrotoxicity in rats: In vivo and molecular docking studies. *Heliyon*, 9(3).



- 24) El-Desouky, M. A. and Mahmoud, M. H. (2019). Nephroprotective effect of green tea, rosmarinic acid and rosemary on N-diethylnitrosamine initiated and ferric nitrilotriacetate promoted acute renal toxicity in Wistar rats. *Interdisciplinary toxicology*, 12(2): 98.
- 25) Molaei, E.; Molaei, A.; Abedi, F.; Hayes, A. W. and Karimi, G. (2021). Nephroprotective activity of natural products against chemical toxicants: The role of Nrf2/ARE signaling pathway. *Food Science & Nutrition*, 9(6): 3362-338.
- 26) Aprilia, V.; Bhima, S. K. L. and Ismail, A. (2018). Pengaruh Pemberian Butylated Hydroxytoluene (2, 6-Di-Tert-Butyl-4-Methylphenol) Per Oral Dosis Bertingkat Terhadap Gambaran Histopatologis Ginjal. *Diponegoro Medical Journal* , 7(2): 1154-1165.
- 27) Ozbek, E. (2012). Induction of oxidative stress in kidney. *International journal of nephrology*, 1:1-10.
- 28) Ansari, F. A. and Mahmood, R. (2016). Sodium nitrite enhances generation of reactive oxygen species that decrease antioxidant power and inhibit plasma membrane redox system of human erythrocytes. *Cell Biology International*, 40(8): 887–894.
- 29) Chen, Q.; Chen, X.; Fu, Z.; Bais, S. and Hou, X. (2019) Anti-amnesic effect of *Leea indica* extract in scopolamine-induced amnesia of Alzheimer's type in rats. *International Journal of Pharmacology* 15, 116-123.
- 30) Luna-Guevara ML; Luna-Guevara JJ; Hernández-Carranza P; Ruíz-Espinosa H and Ochoa-Velasco CE (2018). Phenolic compounds: A good choice against chronic degenerative diseases. In: Atta ur, R. (ed.) *Studies in Natural Products Chemistry*. Elsevier, pp. 79-108.
- 31) Playford, R. J. and Weiser, M. J. (2021). Bovine Colostrum: Its Constituents and Uses. *Nutrients*. 13, 265.
- 32) Young, J. I.; Zuchner, S. and Wang, G. (2015). Regulation of the Epigenome by Vitamin C. *Annu. Rev. Nutr.* 1:(35): 545–564.
- 33) Ryu, M. Y.; Kim, C. Y. and Kim, J. W. (2003). Two new megastigmane glycosides from *Phyllanthus ussuriensis*., 1912-1912.
- 34) Kotb, E. S.; Serag, W. M.; Elshaarawy, R. F.; Hafez, H. S. and Elkhayat, Z. (2021). The protective role of Gallic acid in Cisplatin nephrotoxicity. *Frontiers in Scientific Research and Technology*, 2(1): 48-52.
- 35) Kahkeshani, N.; Farzaei, F.; Fotouhi, M. Alavi, S. S.; Bahramsoltani, R.; Naseri, R. and Bishayee, A. (2019). Pharmacological effects of gallic acid in health and diseases: A mechanistic review. *Iranian journal of basic medical sciences*, 22(3): 225.