



Pathological and Immuno-Molecular Examination of Protozoa in Aborted Fetus's and Placenta of Iraqi Cattle (A case report)

Muna Sachit Hashim¹, Thikra Abdulla Mahmood^{2*}, Ali J. AL-Nuaimi³, Mayada S. Hassan³, Eman Hashim Yousif¹, Taghreed Jabber Humadai¹, Layth Abdulmajeed Abdulkhaleq¹, Hana Salih Abd Ali Alramah¹, Angham Jasem Mohammed Ali⁴

¹ College of Veterinary Medicine, University of Baghdad

² College of Medicine, Dept of Community Medicine, University of Kufa.

³ College of Veterinary Medicine, University of Kerbala

⁴ Medical Technical Institute, University of Al-Furat Alawsat, Kufa.

* Corresponding author: thakraas@gmail.com

Received: July 13, 2022	Abstract Tissue samples of placenta and aborted fetus were collected from aborted cow and preserved in 10% formalin buffered saline for routine histopathology stained with H&E and for immunohistochemistry to detect TNF-a marker. Pathological examination showed necrotic foci with abscesses mainly around site of invasive protozoa. Immuno-Molecular examination showed marked deposition of TNF marker in tissue, mainly brain of fetus, which refers to genetic damage in gene responsible for controlling TNF values. It is concluded that protozoal infection with <i>Neospora caninum</i> can cause abortion in cattle at advanced stage (8 th month) of gestation with severe histopathological lesions on placenta as well as the brain of fetus. This case report is an update for the information presented in the Proceedings of the 3 rd Scientific Conference of the Faculty of Veterinary Medicine / University of Kerbala on 10 th April 2017. Keywords: Abortion; Cow; Iraq; Protozoal
Accepted: Aug. 21, 2022	
Published: Sept. 20, 2022	

Introduction

Abortion is the premature expulsion of the foetus from the mother and usually occurs because the foetus has died in the uterus. If death occurs at 1-2 months of gestation, it is usually termed early embryonic death, and usually resorbed by the uterus with no signs. After 2 months of gestation, there is usually an expulsion of the foetus and placental tissues. Embryonic and foetal deaths deprive the fetal-maternal unit and result in discontinuation of pregnancy [1,2]. Parturition and presumably abortion in most animal species is initiated by the foetal adrenal gland. Perhaps a stressful event causes the foetal pituitary to secrete Adrenocorticotrophic hormone (ACTH) that in turn results in the glucocorticoid production by the adrenal gland. Corticosteroids increase the synthesis of estrogens in the placenta, which in turn causes the synthesis and release of prostaglandins (PGF₂) from the endometri-



um and myometrium. This causes luteolysis and decreased progesterone production [1,3].

In large animals, the loss of very small embryos doesn't influence the time of return to estrus. The next estrus will be somewhat increased because the corpus luteum will be programmed for prolongation of its life [1,2]. Regardless of the sources of hormones responsible for maintaining pregnancy in large animals, embryonic or foetal death permits the release of PGF₂ and expulsion of the embryo or fetus [2]. The exact outcome is unpredictable and is influenced, among other things, by species, stage of gestation, and number of fetuses. In the bitch and queen, the life span of the corpus luteum is not very different between pregnant and non-pregnant animals when embryonic or foetal death occurs in domestic carnivores. The demise of the corpus luteum is definite and dead products of conception may be retained until approximately the normal time of parturition. Fetal autolysis is therefore common [1,2,3].

Neosporosis is a protozoal cause for abortion in cattle. The general name is Coccidiosis. *Neospora caninum* was isolated from aborted cattle and foetuses. The histopathological lesions were primarily multiple necrotic foci with meningitis and encephalomyelitis, and co-emulative necrosis appeared as necrotic foci in the fetus's liver, with necrotic foci on the placenta [2,4]. Placental necrosis accompanied by a heavy inflammatory response resulted in hormonal imbalances that resulted in abortion [5]. The aim of this study is to investigate the role of *Neospora caninum* in causing abortion in Iraqi cattle.

Materials and Methods

Animals: One aborted cattle fetus's tissues and placenta from a cow suffered from abortion (A case report).

Tissue samples: Tissue samples (~1 cm³) were collected aseptically from the placenta of an aborted cow and its fetus (brain) and preserved in 10% formalin buffered saline for routine histopathology stained with H&E and for immunohistochemistry to detect TNF- α marker [6,7,8].

Results and Discussion

Immunohistochemistry: Brain tissue samples of aborted foetus and placentas showed an increase in the deposition of TNF deposition, as well as in placenta (Figure 1).

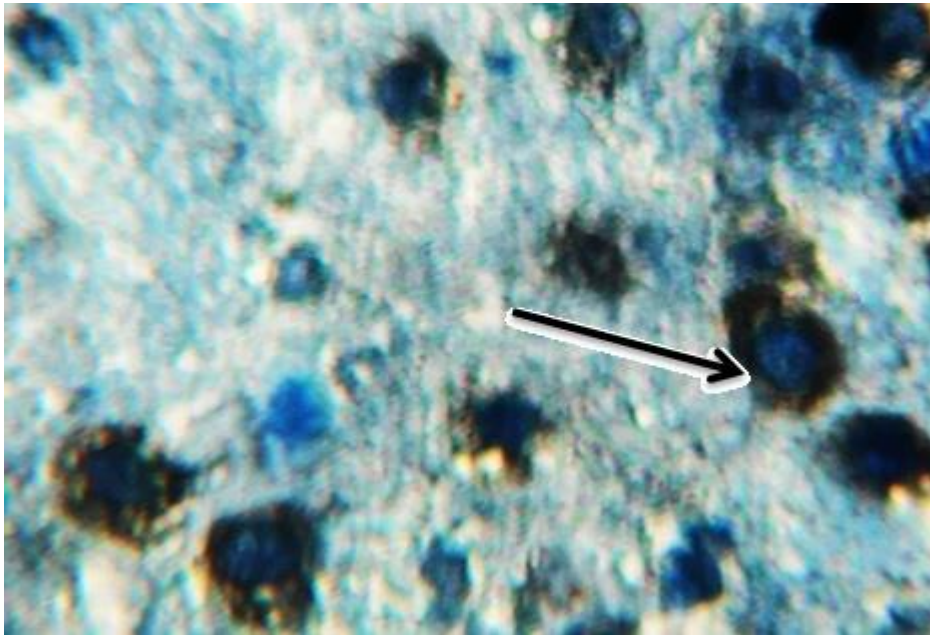


Figure (1): Photomicrograph of brain's fetus showed clear vacuolation in neuron containing black-bluish (arrow) deposition of TNF (Dap (IHC), 40X).

Abortion in cattle in the advanced period (6,9,10) months of pregnancy occurs mainly due to the virulent pathogen *Neospora*, which makes changes in normal apoptosis mechanism and is associated with control necrosis marker besides its effects on genetic material [1,5].

Histopathological changes: Histopathological findings showed necrotic foci around vacuoles containing protozoal infection of *Neosporin caninum* with a zone of fibrous connective tissue (Figure 2). Abortion occurs mainly in the 8th month of pregnancy in association with signs of chronic inflammation characterized by evidence of giant cell (adhesive macrophages) and fibrous connective tissue proliferation (Figure 3).

Abortion causes in Iraq are mainly bacterial but *Neospora sp.* is incriminated in this case reports causing abortion in advanced stage of pregnancy at 8th month of gestation period [1,9]. Previous immunological and molecular studies were used for detection of infection with *Neospora sp.* [10,11] which stipulated the harmful effects of pathogen on tissue structure specially DNA damage [11]. *Neospora caninum* can be tested by fluorescence in situ hybridization methods [5]. Pathological finding on aborted placenta and fetuses tissues in this case report revealed necrosis associated with fibrotic inflammation due to chronicity due to virulent pathogen [12,13]. Infection of fetus brain refers to passing the placenta blood barrier indicating low immune response represented by increase P53 marker responsible for apoptosis and TNF responsible for increase necrotizing lysosome [12]. Elevated estrogen level is responsible for expelling of fetuses and increase serum prolactin [9,13]. Other researchers diagnosed similar pathological lesion mainly necrosis in association with immunohistochemistry application in various infected tissues [7,8]. The presence of dogs among cattle field and direct contact with

food and water highly predicts the incidence of infection with *Neospora caninum* [3,4,14,15].

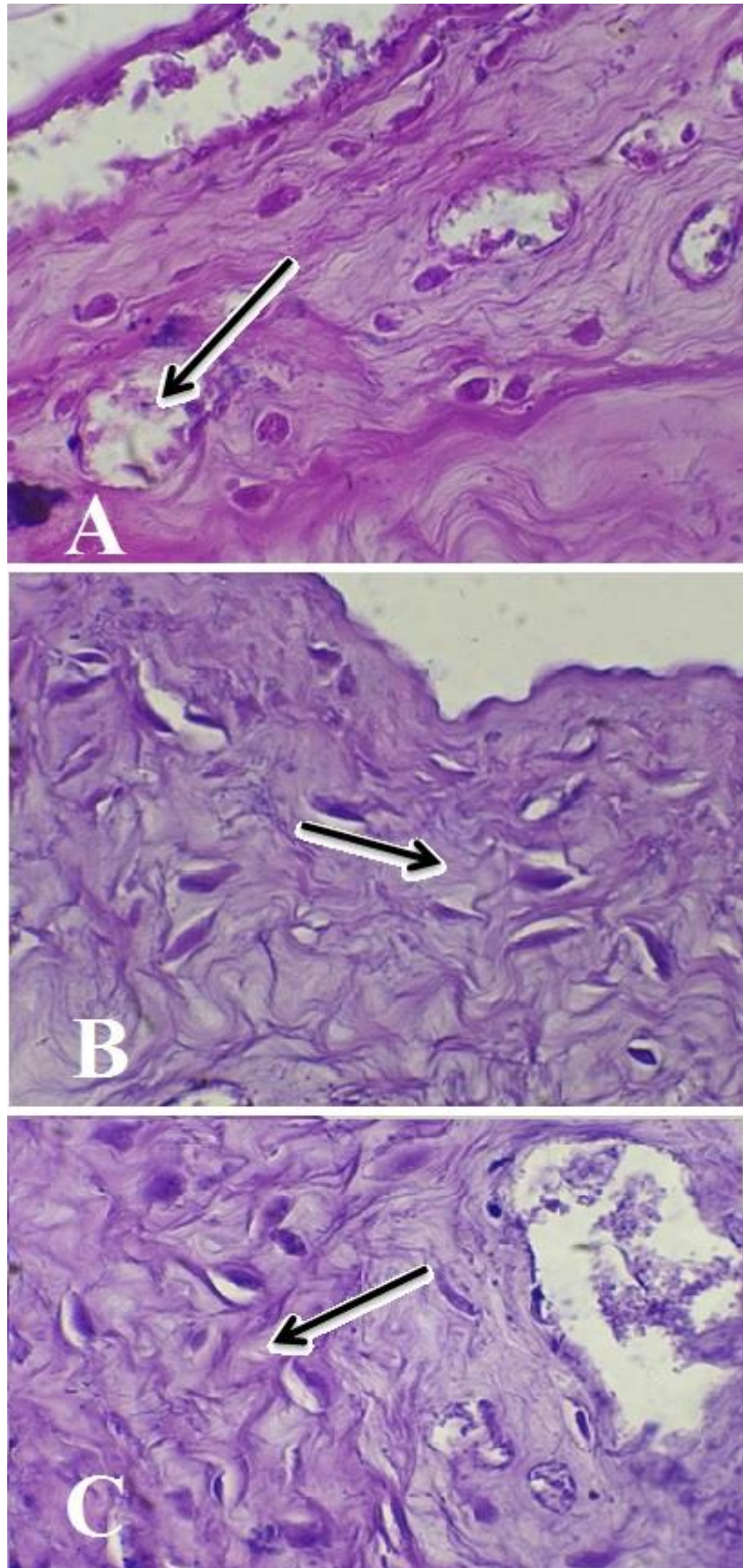


Figure 2 (A, B, C): Photomicrograph of Placenta showed necrotic foci with tissue's depress around vacuoles containing invasive parasite with zone of fibrous tissue (H&E, 40X).

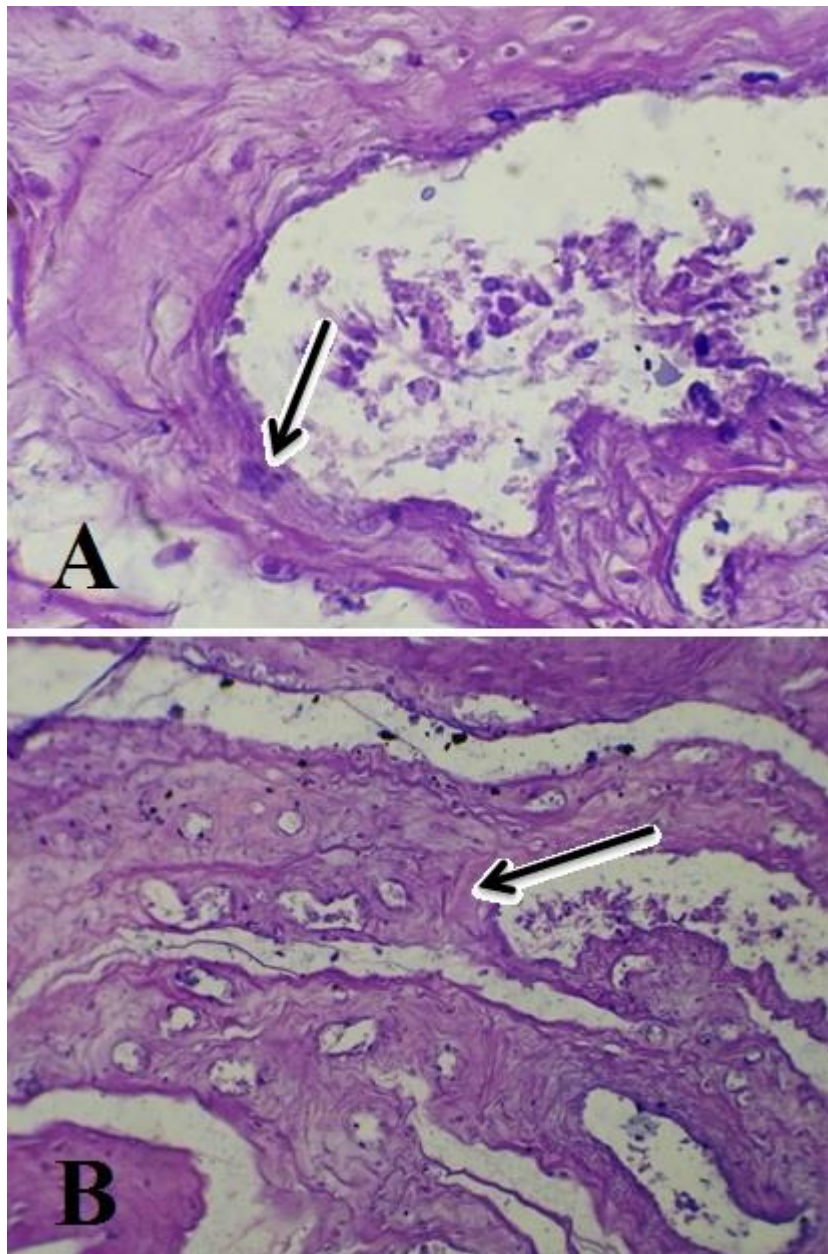


Figure 3(A, B): Photomicrograph of Placenta showed giant cell (H&E, A; 40X, B; 10X).

Protozoal infection with *Neospora caninum* can cause abortion in cattle at advanced stage (8th month) of gestation. Severe histopathological lesions were obvious on placenta as well as the brain of fetus.



References

- 1) Anderson, M.L.; Palmer, C.W.; Thurmond, M.C.; Picanso, J.P.; Blanchard, P.C.; Breitmeyer, R.E.; Layton, A.W.; McAllister, M.; Daft, B.; Kinde, H. (1995). Evaluation of abortions in cattle attributable to neosporosis in selected dairy herds in California. *Journal of the American Veterinary Medical Association*, 207(9): 1206-1210.
- 2) Donald, M.; Gavin, MC.; Zachary, J.F. (2007). *Pathologic Basis of Veterinary Diseases*. Pp:1289-1300.
- 3) McAllister, M.M. (2007). Bovine Neosporosis and Coccidiosis. *Biológico, São Paulo*, 69(2): 57-61.
- 4) Varaschin, M.S.; Hirsch, C.; Wouters, F.; Nakagaki, K.Y.; Guimarães, A.M.; Santos, D.S.; Bezerra, P.S.; Costa, R.C.; Peconick, A.P.; Langohr, I.M. (2012). Congenital Neosporosis in Goats from the State of Minas Gerais, Brazil. *The Korean Journal of Parasitology*, 50(1): 63-67.
- 5) Haddad, J.A.; Dohoo, I.R.; VanLeewen, J.A. (2005). A review of *Neospora caninum* in dairy and beef cattle-a Canadian perspective. *Can Vet J.*, 46(3): 230–243.
- 6) Al-Aamery, M.S. (2013). *Molecular, Pathological and Immunological Study of Vincristine Sulfate Effects in White Male Mice and Rats*. Pp:59-154. PhD Thesis. College of Veterinary Medicine, University of Baghdad.
- 7) Sabrin, I.M.; Tagreed, G.; Muna, S.H. (2019). Examination of Immunopathological changes in Diabetic Mice. *Annals of Tropical Medicine and Public Health*, 22(10):191-203.
- 8) Maha, F.M.; Muna, S.H. (2020). Detection of apoptosis in mice infected with *Salmonella typhimurium* and treated with plant extracts and antibiotics. *Plant Archives*, 20(2): 5053-5059,
- 9) Dubey, J.P.; Schares, G. (2006). Diagnosis of bovine neosporosis. *Vet Parasitol.*, 140: 1–34.
- 10) Jensen, T.K.; Montgomery, D.L.; Jaeger, P.T.; Lindhardt, T.; Agerholm, J.S.; Bille-Hansen, V.; Boye, M. (2007). Application of fluorescent in situ hybridisation for demonstration of *Coxiella burnetii* in placentas from ruminant abortions. *APMIS.*, 115(4): 347-353.
- 11) Lescoat, D.; Jouan, H.; Loeuillet-Olivo, L.; Le Calvé, M. (2005). Fluorescent in situ hybridization (FISH) on paraffin-embedded placental tissues as an adjunct for understanding the etiology of early Spontaneous abortion. *Pregnant Diagnosis*, 25(4): 314–317.
- 12) Dubey, J.P. (2003). Review of *Neospora caninum* and neosporosis in animals. *Korean J Parasitol.*, 41: 1–16.
- 13) Eleni, C.; Crotti, S.; Manuali, E.; Costarelli, S.; Filippini, G.; Moscati, L.; Magnino, S. (2004). Detection of *Neospora caninum* in an aborted goat foetus. *Vet Parasitol.*, 123: 271–274.
- 14) dos Santos, D.S.; Andrade, M.P.; Varaschin, M.S.; Guimarães, A.M.; Hirsch, C. (2011). *Neospora caninum* in bovine fetuses of Minas Gerais, Brazil: genetic characteristics of rDNA. *Rev Bras Parasitol Vet.*, 20: 281–288.



- 15) Schares, G.; Peters. M.; Wurm, R.; Tackmann, K.; Henning, K.; Conraths, F.J. (1997). *Neospora caninum* causes abortions in a cattle herd in North Rhine Westphalia. Dtsch Tierarztl Wochenschr., 104(6): 208-212.