

Research Article

Study the effect of the drug mebetalin on the skeletal system and some anatomical signs in albino rat embryos during the late stage of gestation.

Shaymaa Malik Yasir

Biology Department–College of Education for pure sciences– Kerbala University

Article Info

Article history:

Received 17 - 10 -2023

Received in revised form
26-11 -2023

Accepted 6 -12 -2023

Available online 30- 6 -2024

Keywords: The results of this study revealed that the drug mebetalin stimulated abnormal effects in clinical manifestations, some weight parameters, and some structural deformities in embryos during the late stage of gestation.

Abstract

The therapeutic dose of the drug mebetalin was used at a dose of 135 mg which is a drug described as antispasmodic and convulsive, as well as directly relaxes the smooth muscles in the gastrointestinal tract relieving the pain of contractions in it, 10 pregnant white rats belonging to the type of *Rattus rattus* which were distributed into two sets with five pregnant rats for each of them: the first five pregnant females were treated with distilled water only and were left as control animals, while the other five pregnant rats were injected intraperitoneally with the mebetalin drug from the third day until the twentieth day of gestation at the rate of one dose per day, on the twentieth day of gestation the animals were injected with the last dose in the morning and then in the evening the female rats were dissected after anesthesia after that the horns of the uterus and the embryos inside it were extracted and their body weights of embryos and the placenta were measured and the skeletal deformities of these embryos were also studied after their skeletons were clearing.

The results of present study pointed to that the uterine horns of pregnant rats that were treated with mebetalin suffered from pathological and abnormal signs of the uterine horns which were characterized by a small number of embryos and their heterogeneous distribution and the absorption of some embryos for twenty days of gestation compared with clinical signs of uterine horns and the embryos for twenty days of gestation in control set .

The study data recorded a significant decrease ($p < 0.05$) in the weights of the embryos body and weights of placenta of pregnant rats that were injected with mebetalin for twenty days of gestation when comparing the weights of embryos body and placenta of control rats for the same gestation period.

Results of a study indicated that a significant decrease ($p < 0.05$) in the lengths of the body and lengths of upper and lower extremities in the set of pregnant rats treated with mebetalin of twenty days of gestation comparing with control pregnant rats set for twenty days of gestation and the results of drying of the skeletons of the embryos on the twentieth day of gestation revealed that there were many different structural deformities in the set whose mothers were treated with the drug, compared with the skeletons of the embryos of the control set during the same period of gestation (twenty days).

1- Introduction

The placenta is the path through which the food and oxygen necessary for the growth of the embryos pass and at the same time, various chemicals such as various drugs pass through it stimulating a toxic effects in the bodies of pregnant mothers during the various stages of gestation because most of the drugs when they enter the body do not affect the infected cells only but also affect the healthy cells and tissues of the body causing a disturbance in their cellular metabolism and studies have shown that drugs stimulate bad and serious illnesses in mothers, embryos and adults to the same degree which may cause death in many cases (1).

Among the medical drugs that are used during gestation is the drug mebetalin which is used to relax the muscles and thus reduces or eliminates the cramps causing the removal of pain by directly affecting the smooth muscles of the gastrointestinal tract and this drug was classified as a digestive system disease, being an antispasmodic, so it was used to reduce symptoms associated with colon of all kinds especially mucous spastic and nervous, as well as for the treatment of diarrhea, constipation, colic, and flatulence(2), and its action is based on the effect of the drug on the smooth involuntary muscles of the digestive system directly

2-Materials and methods

The number of animals used in the research is 15 albino rats, 10 females with an average weight of 221 g and age of 3 months, and 5 male rats which were used only to obtain the pregnant rats required in this research, the rats were reared in special cages in the animal house in the College of Education for Girls / University of Kufa and induced the same laboratory conditions of temperature between (21-24) degrees celsius, appropriate ventilation and lighting (12 dark and 12 light) respectively, all animals were given water and diet freely which obtained from the laboratories of their manufacture.

Drug dose

The drug used in this study was mebetalin tablets at a concentration of 135 mg which is

which causes the relaxation of these muscles without any effect on the normal movements of the intestines (3), and it was placed several explanations have been adopted for the action of this drug because in fact the mechanism of its action is mebetalin is not known precisely and one of the most important mechanisms such as this drug is the inhibition of acetylcholine receptors, or it is an anticholinergic synthetic and it may reduce the permeability of channels for ions or stimulate changes in the absorption of water and also inhibit the recovery of the hormone norepinephrine (4) and the most minor and accompanying side effects that mebetalin may cause are dizziness and a skin rash accompanied by itching and redness of the skin while among the most important general effects of the body constipation, loss of appetite, heartburn, and indigestion(5), in addition to dry mouth, headache, insomnia, depression and malaise, irregular and slow heartbeat and it may also cause immune system disorders that may lead to allergic reactions leading to hypersensitivity (6), and among the most important cases in which this drug should not be used is the incidence of porphyria or the presence of allergy to the drug, as well as during gestation (7) and this drug forms are oral tablets and capsules, in addition to an oral liquid (8).

a dose used in humans and from this concentration included in the study was prepared based on the weight of the animals, then this concentration was later dosed to pregnant rats(milligrams / kilogram of body weight)depending on the dilution equation: $V_1N_1=V_2N_2$ (9).

Pregnant animals

Males and females were placed in rats for mating and gestation occurred throughout the night, then the females were examined in the morning to notice the mating plug in her vagina whose presence is an indication of mating or gestation occurring as in a figure (1-2) (10), then the process was repeated several times until a sufficient number of rats was obtained pregnant rats included in the current study.



Figure(1-2): Mating plug

- Study design

This study included one main experiment to study the effect of the harmful drug on the weights of some organs and deformities in the skeleton of embryos for twenty days of gestation, pregnant rats were divided into two sets and each set contained first five animals were left without treatment and were provided

-Anatomy of pregnant rats and embryos extraction.

In the evening of the twentieth day of gestation, and after giving the last dose of the drug to pregnant rats in the morning, then these rats were dissected after anesthesia with chloroform and their abdominal cavities were opened with scissors after placing them on the dissection board, after that the uterine horns were removed from the abdomen and placed in glass petri dishes and the appearances and clinical signs were studied of the horns and embryos inside them in terms of the number of embryos (absorbed and live) and their

-Preparation of skeletons.

Embryos were taken at the age of 20 days of gestation from the two sets and their bodies

-Skeletal examination.

After showing the skeletons of the embryos by clearing it and staining them with alizarin red dye, then they were examined with a

with water and diet only and they were as control animals, while the other five animals were injected with the drug mebetalin in the concentration prepared for the experiment peritoneum. Pregnant animals were treated from the third day of gestation until the twentieth day of it with a single daily dose.

distribution in each horn (right and left) before opening the horns and extracting them with sharp scissors, then the embryos and placentas were washed with physiological solutions and then dried, after that the body weights of the embryos and the weights of their placenta were measured ,then a number of embryos were anesthetized with chloroform for the purpose of clearing their bodies to study the pathological changes in the skeleton of the embryos of the drug set compared with the skeletons of control animals.

were cleared to remove the visceral tissue to obtain the skeletons according to the method of (11).

dissecting microscope to study the abnormal structural changes in the drug-treated set and compare it with the control set on the power x5.

-photographer.

Figures were taken of the uterine horns and embryos inside and outside the horns for clinical signs, as well as figures of the

-Statistical Analysis

The results of the study were analyzed using version 17 of SPSS, and the values of the studied criteria were represented by the mean and standard deviation ($M \pm SD$). Student's t test was also used to analyze the results

3-Results

-Studying the clinical signs of embryos

After dissecting pregnant rats during twenty of gestation and obtaining the uterine horns on which no abnormal changes were observed in terms of the external appearance and the distribution of embryos in the uterine horns as in the figure (1-3), also the clinical appearances of the embryos and placenta were

skeletons of the bodies of the translucent embryos to study the abnormal changes at the stage of 20 days of gestation by compound microscope from a kind of Olympus.

statistically, and the least significant difference (LSD) below the significance level ($P < 0.05$) was used. For the purpose of finding significant differences between the study groups (12).

normal and as in the figure (2-3) in the control set , while the uterine horns of pregnant rats that were treated with mebetalin suffered from pathological and abnormal signs of the uterine horns which were characterized by a small number of embryos and their heterogeneous distribution, and the absorption of some embryos as in the figure (3-3) and the congestion of the embryos with the placenta as in a figure (3-4).

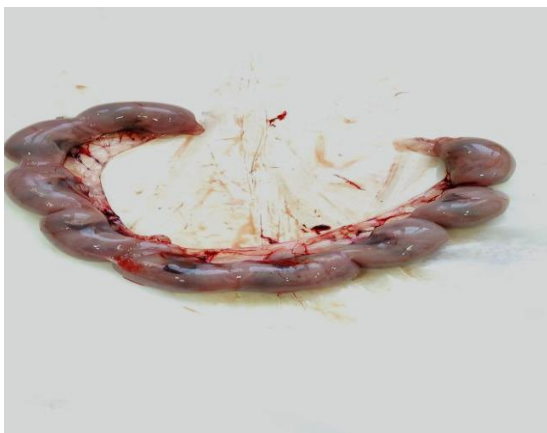

Figure (1-3) The normal uterine horns of pregnant rats from the control group for a 20-days of gestation in it: normal distribution of embryos appears in the uterine horns.

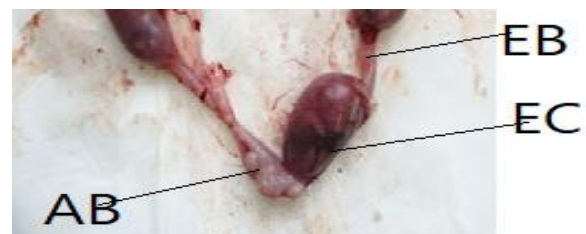
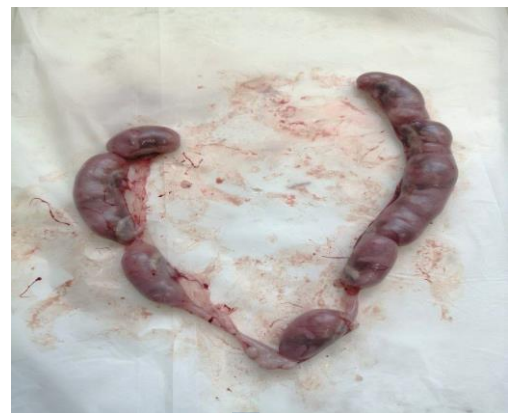
figure (2-3) The uterine horns of pregnant rats from the treated group with mebetalin for a 20-days of gestation in it: abnormal distribution of embryos appears in the uterine horns, Non-implantation of embryos in some parts (EB), Absorbed embryo (AB), the embryo congestion (CE).

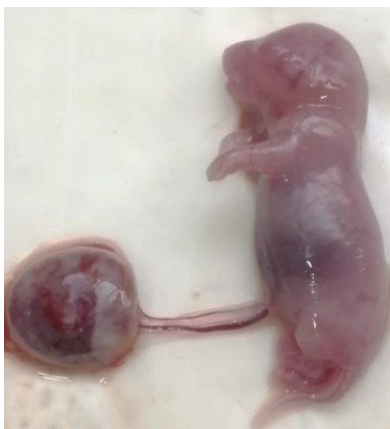

Figure (3-3): Normal embryo and placenta from a control group of 20 days of gestation .

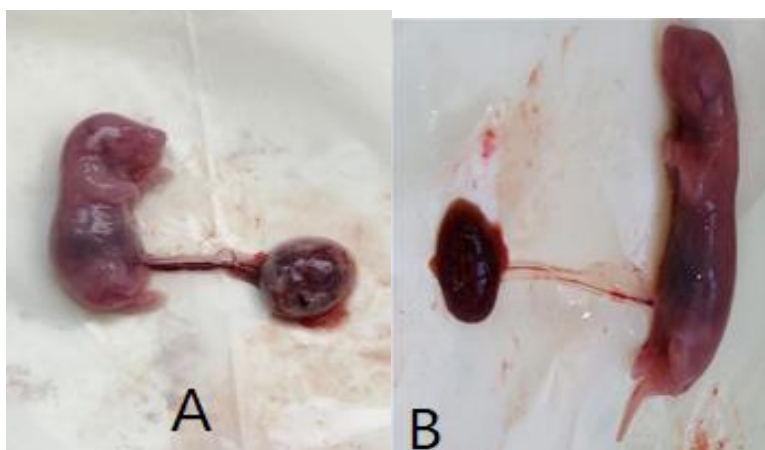


Figure (4-3):Abnormal embryo from treated animals group with drug of 20 days of gestation, (A) Small size of the embryo, (B)congestion of the embryo and placenta.

-Study of body weights and placentas of embryos

The results indicated that there was a significant decrease ($p < 0.05$) in the body weights of the embryos and placenta in the set

of rats treated with mebetalin for a period of 20 days of gestation compared with the body weights and weights of the placentas of embryos during the same period of gestation of twenty days as in table (1-3).

Table 1-3: Study of body weights and placenta of embryos.

Parameters Sets	Weights of body (gm)	Weights of placenta (gm)
Control animals	1.25±0.03	0.95±0.01
Injected animals with drug	0.40±0.02*	0.23±0.02 *
L.S.D	0.30	0.45

Values: mean ± standard error.

*: A significant difference at a probability level ($P < 0.05$).

L.S.D: least significant difference .

N = 5 for each set .

- Studying abnormalities in the skeleton of embryos.

The results of the study showed that a significant decrease ($p < 0.05$) in the lengths of the body and lengths of *upper and lower extremities* in the set of rats treated with mebetalin for a gestation period of twenty days when compared with lengths of these structures of embryos in untreated pregnant rats for the same gestation period above as in table (2-3), and results also indicated there were no deformities or abnormal signs in the

skeletal structures of the embryos during the twentieth day of gestation as in a figure (5-3) in the control set , while in the set treated with the drug under study on the twentieth day of gestation, the skeletons were revealed the appearance of various deformities such as short skeleton causing a short body length for embryos, deformation of the skull and Jaw bone deformity , and loss of phalanx bones of *upper and lower extremities*, and lack of the caudal vertebrae as in the figures(6-3), (7-3) ,(8-3) ,(9-3).

Table 2- 3: Study the lengths of the body , upper and lower extremities of embryos.

Parameters Sets	Lengths of body (cm)	Lengths of upper extremities (cm)	Lengths of lower extremities (cm)
Control animals	4.75±0.02	2.15±0.04	2.95±0.03
Injected animals with drug	3.00±0.05*	1.74±0.03 *	2.00±0.04 *
L.S.D	0.57	0.22	0.35

Values: mean ± standard error.

*: A significant difference at a probability level ($P < 0.05$).

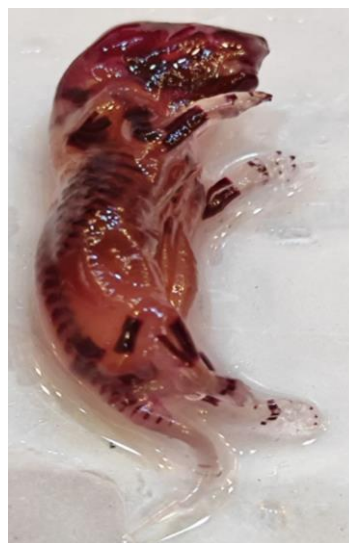L.S.D: least significant difference .

N = 5 for each set .



A

Figure (5-3A): Transparented rat embryo from the control group for a gestation period of 20 days, and it contains: the normal skeleton ,(A) Back view.(Alizarin Red stain (5X)).



B

Figure (5-3B): Transparented rat embryo from the control group for a gestation period of 20 days, and it contains: the normal skeleton (B) Letral view.(Alizarin Red stain (5X)).

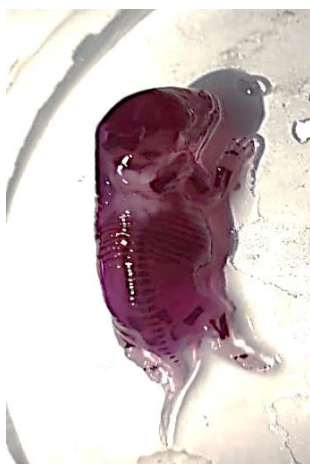

Figure (6-3): Transparented rat embryo from group treated with mebetalin for 20 days of gestation ,in it :- Abnormal and deformed skeleton: Short skeleton (Alizarin -Red dye- (5X)) .

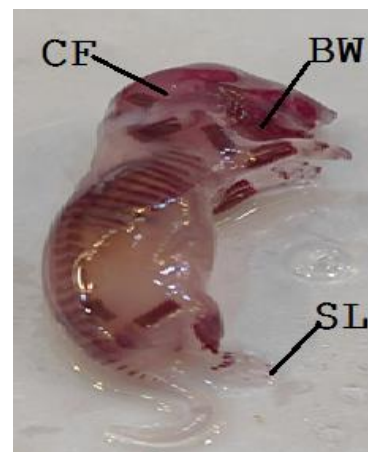


Figure (7-3): Transparented rat embryo from group treated with mebetalin for 20 days of gestation ,in it :- Abnormal and deformed skeleton : Deformation of the skull (CF), loss of phalanges (SL), Jaw bone deformity (BW) (Alizarin-Red dye- (5X)).

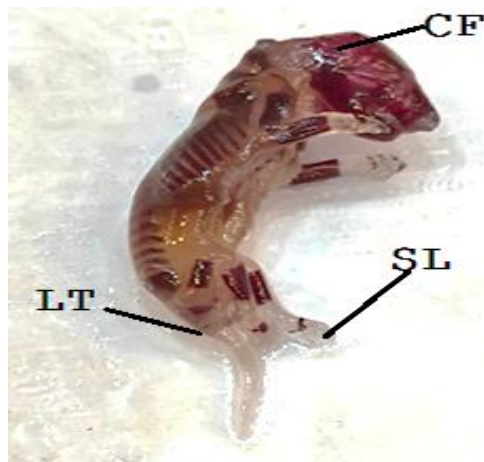


Figure (8-3): Transparented rat embryo from group treated with mebetalin for 20 days of gestation ,in it :- Abnormal and deformed skeleton such as : Deformation of the skull (CF) loss of phalanges of the lower extremities, Lack of caudal vertebrae (LT) (Alizarin-Red dye- (5X)).

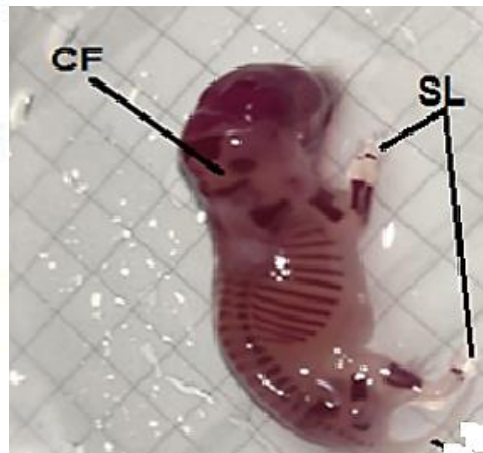


Figure (9-3): Transparented rat embryo from group treated with mebetalin for 20 days of gestation ,in it :- Abnormal and deformed skeleton , Deformation of the skull (CF), loss of phalanges of the upper and lower extremities (SL) (Alizarin -Red dye- (5X)) .

4- Discussion

- Studying the effect of mebetalin on the clinical signs of embryos

Results of current study pointed to the uterine horns and the embryos inside them in the mebetalin-treated set showed abnormal changes in the macroscopic appearance in terms of the distribution of embryos in them and the preparation of live and (absorbed) embryos during gestation when compared with control set and due to the lack of studies dealing with the effect of mebetalin on clinical signs during the different stages of gestation, especially day (20) which is a late stage of it, as the drug affected the preparation of implanted embryos and the growth of the embryos during gestation, causing a delay in their growth and absorption and a decrease in their body weights and placentas and this drug showed harmful effects on the structure and development of the skeletal system of the embryos and this inhibits their integration and formation causing short body length in general, and long tail, front and hind limbs. The current study also showed that embryos were characterized when mothers were treated with the drug mebetalin from the third day of

gestation until the 20th day of it with lack of movement, lethargy, and congestion in embryos and placentas, and because the lack of studies that explain the results of the current study, it is possible that the reason for this is due to this drug has negatively affected the central nervous system of embryos causing lethargy and lack of movement (13), the significant decrease in the preparation of live and deformed total embryos may be explained by the oxidative stress caused by the drug mebetalin as a result of the synthesis of free oxygen radicals, especially the active forms of oxygen that increase the oxidative breakdown in the tissues of the mother, especially in the placenta, causing a lack of nutrients to the embryos and thus the death of the embryos and their adsorption, as the oxidative stress stimulates programmed cell death which leads to fragmentation and destruction of embryonic cells and tissues(14), in addition to failure in the process of embryonic implantation and subsequent embryonic developmental processes as confirmed by some studies in other drugs (15), or the reason for the current results may be due to the fact that mebetalin drug caused a disturbance in the

levels of hormones responsible for the processes of ovulation, implantation and other reproductive processes in females such as hormones of the hypothalamus or pituitary gland (FSH, LH) causing a decrease in the

- Studying the effect of mebetalin on the body weights of embryos and placentas.

The results showed a significant decrease in the body weights of embryos and placentas during the gestation period (20) days in the set treated with mebetalin compared with the control set and due to the lack of studies on the effects of mebetalin on the body weights of embryos and placentas during various gestation stages and in (20) day of female rats treated with this drug, therefore the reason for these results could be that the treatment of female rats with mebetalin from the third day to twentieth of gestation caused negative effects by generating oxidative stress resulting from increased formation of free radicals in the cells of the organs of pregnant rats especially the uterine horns with what it contains of the embryos during the different stages of gestation causing destruction and damage of the tissues of the females, as well as the destruction of the various organs such as the liver, kidneys and brain of the embryos causing a decrease in the body weights of the embryos (16), in addition to the destruction of the tissues of the placenta preventing the access of nutrients and oxygen to the embryos which stimulates a decrease in the weights of the placentas and the weights of the embryos respectively, as a result of oxidative stress

-The effect of mebetalin on fetal structural deformities.

The results of this study indicated that a significant decrease ($p < 0.05$) in the lengths of the body and lengths of upper and lower extremities in the set of rats treated with mebetalin for a gestation period of twenty days when compared with control set for the same gestation period and results also showed occurrence of various structural deformities in embryos during gestation (20) a day with the set that treated with mebetalin compared with the control set and these results of the study can be explained by the fact that mebetalin had a negative effect

number of eggs in which ovulation occurred and thus a decrease in the number of corpus luteum in the ovaries and the number of implanted embryos.

which stimulates the oxidative breakdown in the tissues of the mothers and embryos, or may explain the result of this study that treatment with this drug under study, and it stimulated various harmful effects in embryos as a result of the lack of endogenous antioxidant means in the body of embryos that are poorly developed in the early stages of embryonic development stimulating oxidative stress when treated with this drug resulting from poor balance between high oxidation products and antioxidant means and this leads to failure of development and growth in embryos at different stages especially during advanced stages of gestation causing a decrease in body weights of embryos and placentas as a result of oxidative breakdown of body tissues of embryos and placenta (17), or may the reason for the decrease in the body weights of the embryos is due to the oxidative stress stimulated by the drug mebetalin, as it affected the skeleton structures of the embryos causing deformities in the skeleton resulting in deformed embryos with structural deformities and this is what the current study showed which leads to a decrease in the body weights of the embryos which increases with an increase in the dose of the drug and duration of gestation (18).

on the bone cells that enable bone fractures causing the prevention of bone formation within the cartilage in some parts of the skeleton, or the reason may be due to the effect of mebetalin on the genes responsible for the formation of the skeleton inhibiting its integration, or it may be due to the role of the drug in generating free radicals that stimulate oxidative stress in bone tissue through the process of oxidation of pedis in cell membranes and other cell components such as proteins and others causing the components of bone cells are destroyed and thus deformities occur in the embryonic skeleton (18), or the results of the current study may be explained

by the fact that thi drug under study inhibits the transformation of cartilage into bone due to its activity in preventing ossification of cartilage into bone, especially during the late stages of pregnancy which was not revealed by this study because the alizarine- red dye only dyes bone structures and not cartilage that needs dyes other special ones such as the blue allicin dye that color the cartilages in the body of embryos(11, 18) ,or the reason for these deformities in the skeletal system of the

embryos whose mothers were treated with mebetalin drug may be attributed to the fact that it stimulated harmful effects in the various body systems of the mothers causing the destruction of their tissues especially the placenta preventing the arrival of nutrients to the embryos especially those that work to build bones such as vitamins and minerals, etc., especially in the early stages of gestation which reflected on the embryos in the late stage of gestation(19).

5-References

- 1- Aktes,A.;Nergiz,Y.;Akkus, M . and Nasir , Y. (2010). The effects of valporic acid on renal corpuscle of pregnant rats and protective of folic acid and vitamin E. African . J. Bio chem., 9(34): 5605-5610.
- 2- Ares- Block, D .(1997) . Effects in repeat-dose toxicity studies, after oral and parenteral doses, were indicative of central nervous. Odyssey Business Park ‘ Ares Block. ‘West End Road ‘South Ruislip ‘Middlesex ‘HA4 6QD .
- 3- Darvish-Damavandi, M.; Nikfar S. and Abdollahi, M .(2010). "A systematic review of efficacy and tolerability of mebeverine in irritable bowel syndrome". *World Journal of Gastroenterology*. 16 (5): 547–553.
- 4- Hatami ,M.; Farhadi, K. and Tukmechi ,A. (2012). Fiber-based liquid-phase micro-extraction of mebeverine enantiomers followed by chiral high-performance liquid chromatography analysis and its application to pharmacokinetics study in rat plasma". *Chirality*. 24 (8): 634–9. doi:10.1002/chir.22057. PMID 22700279.
- 5- Annahazi ,A.; Roka ,R.; Rosztóczy ,A. and Wittmann, T .(2014). "Role of antispasmodics in the treatment of irritable bowel syndrome". *World J. Gastroenterology*. ,20 (20): 6031–6043. doi:10.3748/wjg.v20.i20.6031. PMC 4033443. PMID 24876726.
- 6- Daniluk, J.; Malecka-Wojcieszko ,E. ; Skrzydło-Radomska ,B and Rydzewska,G.(2022). The Efficacy of Mebeverine in the Treatment of Irritable Bowel Syndrome—A Systematic Review.*J .Clin. Med.*, 11(4): 1044. doi: 10.3390/jcm11041044
- 7- Kim, J. W.(2012). Is Otilonium Bromide Really Effective for Treating Asian Patients With Irritable Bowel Syndrome? *J .Neurogastroenterol. Motil* 18(1): 109-110 . <https://doi.org/10.5056/jnm.2012.18.1.109>
- 8- Gilbody, J ..S.; Fletcher, C .P.; Hughes, I .W.and Kidman, S. P.(2022). Comparison of two different formulations of mebeverine hydrochloride in irritable bowel syndrome. *Intel. J. Clin.Practice* .,54(7):461-464.(Article). doi:10.1111/j.1742-1241.2000.tb10900.x
- 9- Rajasekaran, U. and Nayak, U. (2014).How to choose drug dosage for human experiments based on drug dose used on animal experiments: a review. *IJSS .Case. Rep. Rev.* .,1:31-2.
- 10- Fox,T.;Barthold ,S.; Davisson , M .;New Comer, C.; Qumby ,F. and Smith A.(2006). The mouse and biomedical research : Normative . Biol .Husbandry .Med . Edition . , Elsevier .
- 11- McLeod , M . J. (1980). Differential Staining of cartilage and bone in whole mouse embryo es by alcian blue alizarin reds . *Teratology* ., 22 : 299-300 . 12- Morgan,G.A.;Leech,N.A.;Gloecner,G .W.andBarrett,K.C.(2010).SPSS for introductory statistic:usea introduction .2nded.Lawrenz Erlbaum association publishers Mahwash,New Jersey. London.
- 13- AL- Essawi, D. A-H. K.; Abed ,A.K.; Yahya ,W.H.; Alhadad,A.S.I. and Mohammd ,Z.M.(2020).,Protective

- impact of vitamin C against some fetal and neonatal congenital malformations and anti-inflammatory non-steroidal – induced hepatotoxicity of white rats .
Sys.RevPharm. 11(11):621-631.
<http://www.sysrevpharm.org/?mno=4099>.
- 14- Iborra,A.;Palacio,J. and Martines,P.(2005).Oxidative stress and autoimmune response in the infertile women.Chen.Immunol .Allerg., 88:150-162.
- 15- AL– Essawi, D. A-H. K.(2020).Effect Study A Nonsteroidal Antiinflammatory Drug (Indomethacin) on Fertility, Some Reproductive Norms and Histological Changes of Fetuses and Newborns of Administered Albino Rats Before Pregnancy. Sys Rev Pharm., 11(12):17411756.
- 16- Champer ,C.H . and Scialli ,A.R.(2014) Teratogenesis and Environmental Exposur ,in : Creasy and Resniks Maternal-Fetal medicine by Resnik, R,; Greene, M. F ,;Lams ,J.D,; Lockwood , Ch .J,; Moore Th. R., seven edition . Elsevier Saunders ,Philadelphia .
- 17- Wise .L .D.(2016).Numeric of teratogenic severity from embryo –fetal development toxicity studies .Birth ,Defects .Res.B. Dev .Reprod .Toxicol., 107(1):60-70.
- 18- Al–essawi, D. A-h. K .and Aljamali, S. M.J.(2019). The protective influence of vitamin C against different skeletal malformations in prenatal embryos and postnatal newborns of female rats treated with indomethacin during pregnancy . J. Intel .Pharm. Res., 46(4): 1-12.
- 19- Shahin , M.A.; Ramadan , R.A .; Saer , M . and sabry , S .(2011). The effect of the non-steroidal anti-inflammatory drug diclofenac sodium on the embryos of albino mice .Egyption .J. Hospital .Med ., 44: 272-283.